

Assessment of the anterior chamber angle and depth

Claire McDonnell FAOI

Assessment of the anterior chamber angle (ACA) and anterior chamber depth (ACD) is necessary for several reasons. Many types of glaucoma require ACA assessment for a correct diagnosis eg, narrow angle glaucoma, angle closure glaucoma, pigmentary glaucoma and neovascular (or 100-day) glaucoma. Visualisation of the angle is also recommended where there is any suspicion of peripheral anterior synechiae, angle recession or iridodialysis post-trauma. It is also useful for establishing the patency of peripheral iridotomies and a patient's suitability for anterior chamber implants. In everyday practice it is useful to know the width of the angle to help determine the potential risk of angle closure prior to carrying out pupil dilation on a patient. This article describes the various methods that can be used to assess the ACA and/or ACD in clinical practice.

42

15/10/10 CLINICAL

Pen torch method

The simplest method of assessing ACD is by shining a pen torch into the patient's eye from the temporal canthus such that the pen torch lies in the same plane as the eye. In the case of a deep anterior chamber, the iris lies flat and the whole iris will be illuminated. In the case of a very shallow anterior chamber the iris lies forward, blocking some of the light and very little of the iris is illuminated. Based on the amount of eye illuminated the ACD can be graded (Figure 1).

Smith's method

The Smith method is a quantitative method of measuring the ACD.¹ It is carried out using a slit lamp with the observation system directly in front of the patient's eye and the illumination system at an angle of 60° to the temporal side. If measuring the patient's right eye,

the right ocular of the slit lamp is used and vice versa for the left eye. A beam of approximately 1.5mm thickness, with its orientation horizontal, is placed across the cornea. The technique is slightly easier if the tear film is stained with fluorescein. A second horizontal beam is then seen in the plane of the crystalline lens (Figure 2a). The length of the beam is adjusted until the beams on the cornea and crystalline lens just appear to meet (Figure 2b). The length of the beam is read directly from the slit lamp and this number is multiplied by 1.34 to calculate the ACD. Eyes with an ACD of less than 2mm should be dilated with caution.

Van Herrick's technique

Van Herrick's technique² is perhaps the most commonly used qualitative method of assessing the size of the ACA using a slit lamp biomicroscope. It

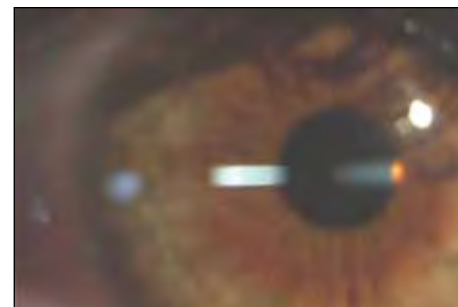


Figure 2a

Measurement of the anterior chamber depth using Smith's method (see text for details)




Figure 2b

Measurement of the anterior chamber depth using Smith's method (see text for details)

involves comparing the size of an optic section width on the cornea to the gap between the section and the reflection on the iris when a beam is trained just within the limbus at an angle of 60°. The section must be just within the corneal side of the limbus. The further it is from the limbus the more the angle will be overestimated. An angle of 60° should be used consistently to allow for standardisation of measurements. The AC angle width used to be graded on a scale of grade 0 (closed) to 4 (wide open) but this meant that subtle changes in angle width could easily be missed. Today it is more common to grade the angle on a decimal scale (see Table 1). For example, a grade of 0.2 (Figure 3) indicates a very likely probability of angle closure occurring, whilst a grade of 1.0 (Figure 4) indicates an almost impossible chance of angle closure occurring.

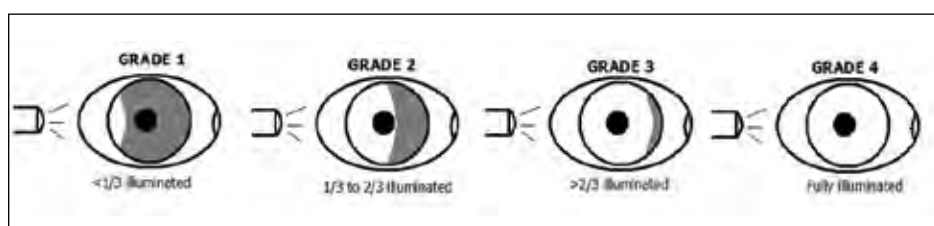


Figure 1

Grading of anterior chamber angle/depth using the pen torch method

Split limbal technique

The Van Herrick's technique can be used to measure the width of the angle temporally and nasally but tells us nothing about the superior and inferior angles. The superior angle is the narrowest and the most likely to close. To estimate the superior and inferior angles the split limbal technique can be used. In this technique the slit lamp is used to provide the illumination but observation is with the naked eye. With the illumination in the click position, a vertical slit should be placed across the superior ACA at 12 o'clock. Observe the arc of light falling on the cornea and iris without the aid of the slit lamp eyepieces. The angular separation seen at the limbal corneal junction is an estimation of the anterior chamber angle depth in degrees (Figure 5 and Table 2).

Optical coherence tomography

Optical coherence tomography (OCT) uses low coherence interferometry to obtain cross-sectional images of the ocular structures. To image the anterior segment, longer wavelength light (1,310nm) is used than that used for the posterior eye. Anterior segment OCT can be used to take measurements of the angle and to visualise, for example the patency of peripheral iridotomies, and blebs in trabeculectomies etc. The Haag-Streit slit lamp OCT is available as an attachment for the slit lamp and the new Cirrus HD-OCT from Carl Zeiss. combines both anterior segment and posterior segment OCT.

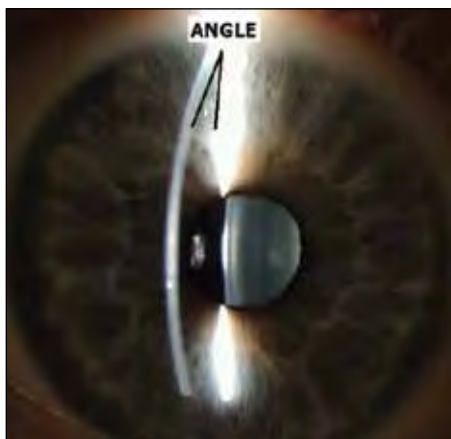


Figure 5
Split Limbal Technique to measure the superior anterior chamber angle




Figure 3
Anterior chamber angle graded as Van Herrick's Grade 0.2



Figure 4
Anterior chamber angle graded as Van Herrick's Grade 1.0

Scheimpflug imaging

The Oculus Pentacam uses Scheimpflug images to create an image of the anterior chamber. The Scheimpflug principle images the anterior eye with a camera at an angle to a slit-beam creating an optic section of the cornea and lens. The image

can give a complete representation of the anterior chamber, extending from the endothelium to the posterior surface of the lens. The geometry of the anterior eye chamber is calculated in three dimensions. The chamber angle is also shown in the Scheimpflug image (Figure 6).

| Van Herrick Grade | Limbal Section: Optically dark section ratio | Probability of closure |
|-------------------|--|------------------------|
| Grade 0.0 | No dark section visible | Closed |
| Grade 0.1 | 1:1/10 | Very likely |
| Grade 0.2 | 1:1/5 | |
| Grade 0.3 | 1:3/10 | Possible |
| Grade 0.4 | 1:2/5 | |
| Grade 0.5 | 1:1/2 | Unlikely |
| Grade 0.6 | 1:3/5 | |
| Grade 0.7 | 1:7/10 | |
| Grade 0.8 | 1:4/5 | Impossible |
| Grade 0.9 | 1:9/10 | |
| Grade 1.0 | 1:1 | |

Table 1

Grading of the anterior chamber angle using the Van Herrick's technique

| Grade | Estimated Angle | Estimated Angle |
|---------|-----------------|-----------------|
| Grade 0 | 0° | Closed |
| Grade 1 | ≈10° | Very likely |
| Grade 2 | ≈20° | Possible |
| Grade 3 | ≈30° | Unlikely |
| Grade 4 | ≥45° | Impossible |

Table 2

Grading of the superior anterior chamber angle using the Split Limbal technique

| Grade | Structures Visible | Probability of Closure |
|-------|------------------------------|------------------------|
| 0 | None | Closed |
| 1 | Only Schwalbe's line visible | Very likely |
| 2 | Trabecular meshwork visible | Possible |
| 3 | Scleral spur visible | Unlikely |
| 4 | Ciliary body visible | Impossible |

Table 3

Grading of the anterior angle with gonioscopy

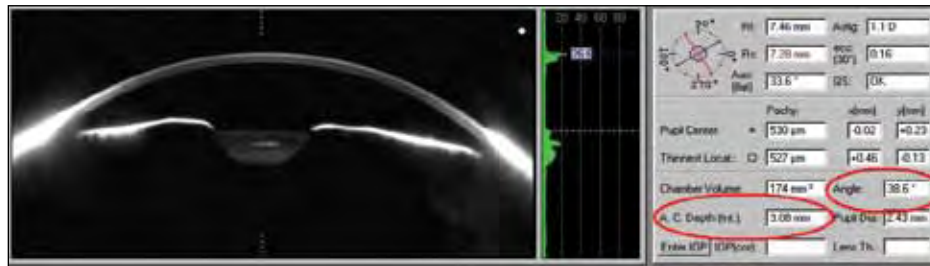


Figure 6

Anterior chamber image and biometry as obtained using Scheimpflug images from the Oculus Pentacam

Gonioscopy

The gold standard for ACA assessment is gonioscopy. This is a technique that is commonly performed in a hospital eye department and involves the use of a slit lamp and gonio-lens. The gonio-lens is a contact lens with mirror(s) and prisms attached to it, which allow direct visualisation into the ACA. To carry out gonioscopy, the cornea is anaesthetised

using topical anaesthetic. A lubricating gel eg, Gel Tears is then added to the gonio-lens before it is placed against the patient's eye. Lenses with a phlange (or lip) are a little easier to keep on the eye as the phlange stays just under the eyelid making it more difficult for the patient to accidentally blink the lens out.

Lenses are available in one, two, three and four mirror designs. The advantage

of a four-mirror lens is that less rotation of the lens is required – a part of the procedure that patients tend to find a little unpleasant. With gonioscopy any abnormalities within the angle eg, pigment deposition, neovascular growth etc. can be detected and the width of the angle can be graded depending on which structures are visible (Figure 7 and Table 3). The width of the angle can be underestimated if the patient is not fixating in the direction of the mirror ie, if the mirror is superior, the patient should look up slightly. The structures visible in a wide angle are (from iris to cornea) (a) the ciliary body (CP): this appears slightly darker than the iris itself, (b) the scleral spur (SS): a white band just above the ciliary body, (c) the trabecular meshwork (TM): this can be a whitish-grey or pink colour, and (d) Schwalbe's line (SL): this is at the edge of Descemet's membrane. In Figure 7 above Schwalbe's line, another apparent line can be seen but this is in fact the corneal reflection.

Conclusion

A full assessment of the ocular health should include some examination of the ACA and/or ACD. While not all optometrists would have access to OCT or be familiar with the technique of gonioscopy, all optometrists should have access to a slit lamp and could therefore be able to easily carry out some of the procedures outlined above. The depth of the anterior chamber naturally decreases with age due to the increase in size of the crystalline lens and with this decrease comes an increased risk of narrow and closed angle glaucoma.

About the author

Claire McDonnell is a lecturer in the Department of Optometry at the Dublin Institute of Technology where she teaches advanced clinical techniques to optometry undergraduates and qualified practitioners.

References

1. Smith RJ. A new method of estimating the depth of the anterior chamber. *Br J Ophthalmol.* 1979;63:215-220.
2. Van Herick W, Shaffer RN, Schwartz A. Estimation of width of angle of anterior chamber. Incidence and significance of the narrow angle. *Am J Ophthalmol* 1969;68:62-9.




Figure 7

The visible structures of the anterior chamber angle during gonioscopy. CP = ciliary body; SS = scleral spur; TM = trabecular meshwork; SL = Schwalbe's line