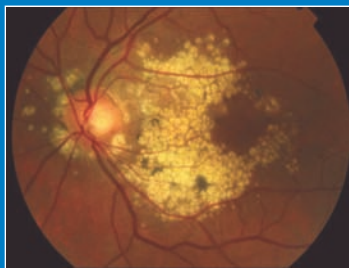


Optometric management of posterior segment eye disease – Macular disorders



Louise O'Toole

This third article of the Optometric Management of Posterior Segment Eye Disease series will concentrate on the differential diagnosis and clinical signs and symptoms of macular disorders. Emphasis is placed on decision-making skills and available treatments will be reviewed where appropriate

Anatomical features

The macula measures 5.5-6.0mm in diameter or approximately 4 disc diameters. It has a circular shape and the centre of the macula is situated 4mm temporal and 0.8mm to the centre of the optic disc. Within the macula, there is a central pit termed the fovea. It measures 1.5mm wide and can be recognised on ophthalmoscopy by an oval light reflex. This occurs secondary to the increased thickness of the retina and internal limiting membrane in the surrounding area. The floor of the depression is called the foveola, measuring 0.33mm. It is the thinnest point of the retina and no ganglion cells are present here. The deepest point of the foveola is named the umbo. The foveal avascular zone (FAZ) measures approximately 0.35-0.50mm in diameter and can be visualised by using fundus fluorescein angiography (FFA).

Symptoms of macular disorders

Patients with macular disease may complain of a reduction in central acuity or have difficulties with their

colour vision - red green colour defects are often indicative of optic nerve disease whereas blue yellow defects point to retinal abnormalities. This finding is termed Kollner's rule.

Patients may also complain of image distortion, termed metamorphopsia, which can easily be picked up using the Amsler grid - a useful tool to detect early maculopathy. Specific descriptions indicate different conditions. Patients will complain of diminution of image size (micropsia) when their foveal cones are physically separated - a feature of central serous retinopathy. When a patient with maculopathy notices a scotoma, it is a positive phenomenon in that the patient is aware that something is blocking their vision. This contrasts with the negative scotomas produced by optic nerve lesions. Here the patient is aware of a gap in their vision.

When patients have macular disease, they are often photosensitive and take a prolonged time to recover when tested using the photostress method. Contrast sensitivity may also be reduced in patients with macular disease.

Disorders of the macula may be either congenital or acquired. Those which have a hereditary basis may not be obvious at birth, the patient becoming symptomatic only in the middle decades of life. The more common hereditary macular disorders include Best's disease, Stargardt's disease, cone and pattern dystrophies as well as X-linked juvenile retinoschisis and North Carolina dystrophy and will now be discussed in detail.

Many macular dystrophies present with a functional deficit but have minimal visible fundus changes (e.g. rod monochromatism or Stargardt's disease), whereas other dystrophies are detected with visible changes and little or no functional defect (e.g. North Carolina macular dystrophy). It is important to note that during disease evolution, a stage of one dystrophy may appear similar to another stage of an entirely different dystrophy (e.g. adult-type foveomacular vitelliform dystrophy may resemble Best's vitelliform dystrophy). Therefore, electrodiagnostics and genetic studies

CONFUSED ABOUT CET REQUIREMENTS? www.cetoptics.com/cetusers/faqs/

IMPORTANT INFORMATION

Under the new Vantage rules, all OT CET points awarded will be uploaded to its website by us. All participants must confirm these results on www.cetoptics.com so that they can move their points from the "Pending Points record" into their "Final CET points record". Full instructions on how to do this are available on their website.

are important aids in differentiating the various macular dystrophies.

Best's disease

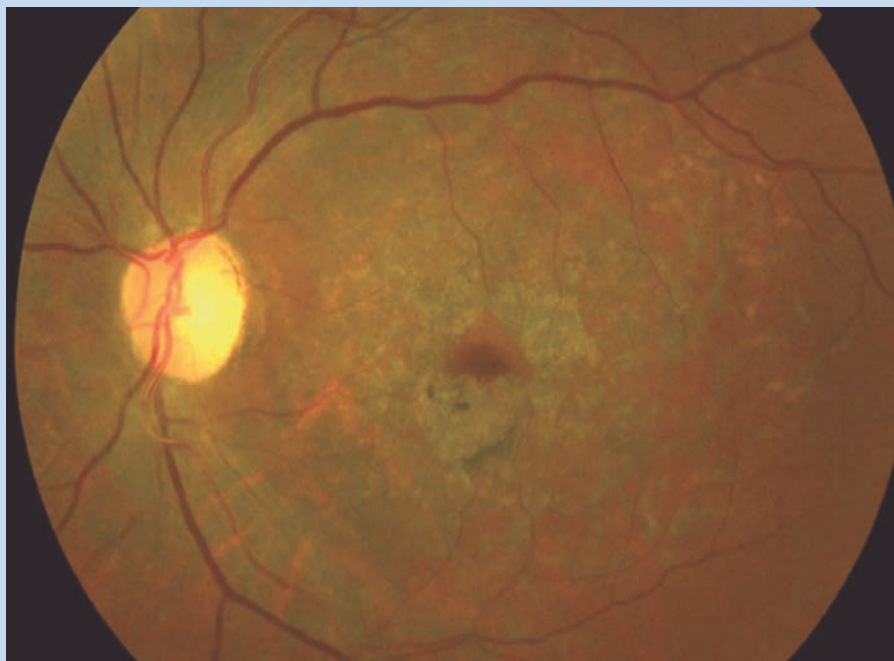
Best's disease is an autosomal dominant disease whose gene has been mapped to chromosome 11q13. It is characterised by an accumulation of a lipofuscin-like material within the retinal pigment epithelial cells of the macula. Symptoms tend to develop in early childhood. There are five clinical stages in disease progression - the first stage is preclinical where patients show no abnormality. However, the electro-oculogram is abnormal at this stage and this is a useful finding allowing families to be screened. The second stage is the vitelliform stage when an egg-yolk like lesion forms in the centre of the macula. Vision may still be normal at this stage. By the second or third decade of life, Best's disease has generally progressed to the third stage - the pseudohypopyon stage. The egg-like lesion then proceeds to break up and evolve into the vitelliruptive stage. At this point, patients notice a reduction in their central vision. The final stage of the disease is characterised by subretinal fibrosis. In general, most patients retain reading vision until the later decades of life. Severe visual loss tends to be slow but may be complicated by a choroidal neovascular membrane (CNVM). Best's disease may also be multifocal.

Stargardt's disease

Stargardt's disease is typically an autosomally recessive inherited condition. The abnormal gene is located on chromosome 1. This gene codes for an energy binding protein - ATP-binding transport protein (ABCR). If the gene mutation is homozygous rather than heterozygous, fundus flavimaculatus ensues.

In typical Stargardt's disease, the retina shows discrete yellow pisciform (shape of a fish) flecks which are confined to the posterior pole. In fundus flavimaculatus, these abnormalities which are at the level of the retinal pigment epithelium (RPE) are seen throughout the fundus.

Patients with Stargardt's disease tend to present in childhood with a bilateral



➔ **Figure 1**
Late Stargardt's disease

gradual reduction in their central vision. In the early stages of the disease, only a slight mottling at the fovea may be seen. With disease progression, the macula assumes a "beaten bronze" appearance. Eventually, a "bull's eye" pattern of retinal pigment epithelial loss occurs and there is an accumulation of lipofuscin-like material in the RPE (figure 1). This accumulation of material blocks the normal choroidal fluorescence seen in a retinal angiogram and this phenomenon is termed a "dark choroid". Patients tend to reach the point of legal blindness by their third or fourth decade. The visual prognosis of patients with fundus flavimaculatus is better than Stargardt's disease unless a fleck involves the foveola.

Cone dystrophy

The inheritance pattern of cone dystrophy is generally autosomal dominant. Early symptoms experienced include a reduction in visual acuity particularly in bright light. Patients also experience difficulties with colour vision and suffer central visual field defects. On examination, initial fundal changes are a pigmentary stippling of the posterior pole. This progresses to a "bull's eye"

pattern in advanced disease. Electrodiagnostic testing shows a grossly abnormal electroretinogram. Visual loss is gradual but may be profound.

Butterfly dystrophy

The pattern dystrophies encompass a group of disorders whose inheritance pattern tends to be autosomal dominant. There is a symmetrical accumulation of pigmented deposits in the maculae. However, few of the dystrophies are exclusive to the macula - panretinal involvement is evident following electrodiagnostic testing. The most commonly observed subtype is the "butterfly" pattern where there is a symmetrical reticular pattern of pigmentation. The lesions are more easily seen using FFA. This disorder becomes manifest in the second to fifth decades and is accompanied by normal or only slightly decreased vision.

X-linked juvenile retinoschisis

X-linked juvenile retinoschisis was first described by Haas in 1898. It is an X-linked recessive condition with 100% penetrance - the abnormal gene is mapped to the short arm of the X chromosome. Only males are affected and electroretinographic abnormalities

indicate that the abnormality is at the level of the Müller cell. Female carriers have both a normal clinical examination and normal electrophysiological testing.

In X-linked juvenile retinoschisis, there is a split between the nerve fibre and ganglion cell layers. There is a spectrum of phenotypical presentations - the pathognomonic finding is a radial cystic maculopathy. Peripheral retinoschisis is present in 50% of patients which may be complicated by retinal detachments and vitreous haemorrhages.

The visual outcome of X-linked juvenile retinoschisis is variable and cannot be predicted based on the fundus findings alone. Visual acuity is usually in the 6/18 range in the affected young adult and may remain stationary for many years, with gradual deterioration to about 6/36 by the sixth decade. Most affected patients are legally blind by the seventh decade.

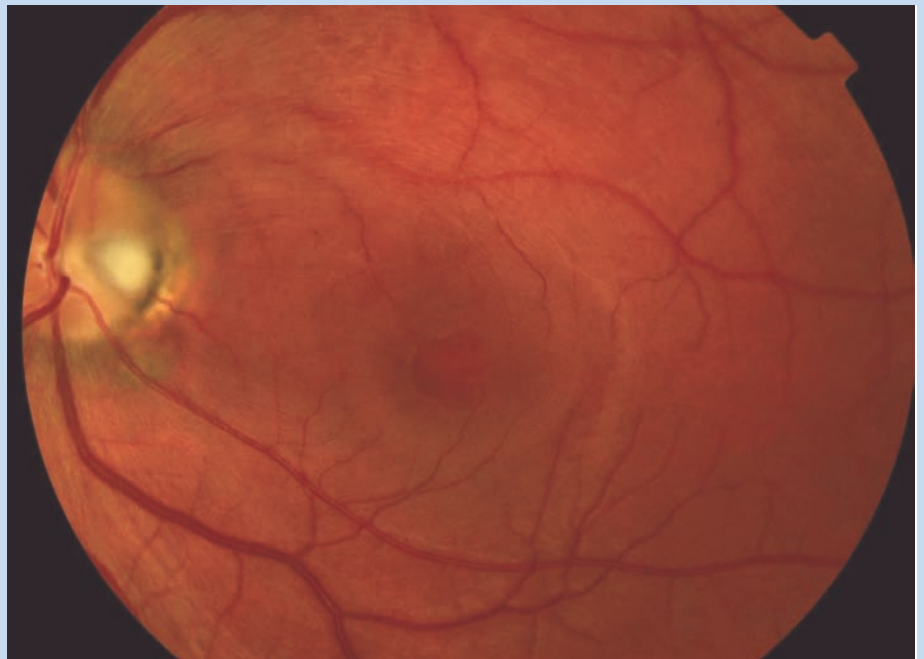
North Carolina dystrophy

North Carolina dystrophy becomes apparent in early childhood when there are scattered drusen and pigment dispersion within the fovea. Visual function is initially good. However, with time there is progression to total pigment epithelial and choriocapillary atrophy at the maculae and consequently poor visual function.

Central serous retinopathy

This disease is most common in middle-aged males but may also affect females. It is thought to be exacerbated by the use of corticosteroids. Central serous retinopathy (CSR) has been linked to raised levels of cortisol, Type A personalities (as a result of stress), pregnancy and hypertension.

Patients typically present with a sudden drop in central vision and metamorphopsia. A positive scotoma may be present. On examination, a serous detachment of the macula may be evident. The fellow eye may show signs of previous subclinical involvement in that there may be hyperpigmentary changes at the macula. FFA and ocular coherence tomography (OCT) will help to confirm the diagnosis. There are two characteristic leakage patterns



➔ **Figure 2**
Macular hole

associated with CSR on FFA - 'smokestack' and 'inkblot'. The majority of patients undergo a spontaneous resolution within three months, although some patients develop a more chronic course. Laser photocoagulation to the point of leakage of the RPE can then be undertaken.

Macular epiretinal membranes

Macular epiretinal membranes are synonymous with cellophane maculopathy. Macular epiretinal membranes may be either idiopathic or secondary to ocular pathology. They are described in association with uveitis, previous surgery, trauma, branch retinal vein occlusions and retinal breaks. Symptoms will depend on the thickness of the epiretinal membrane, the degree of retinal distortion caused by the overlying membrane, the presence or absence of significant traction, which can cause a microdetachment of the posterior pole, and whether or not oedema is present in the macular and perimacular regions. Thin epiretinal membranes usually cause few symptoms and the condition is usually relatively stable or slowly progressive. In more advanced cases, there is a reduction in vision,

micropsia, metamorphopsia, Amsler grid distortion, and occasionally monocular diplopia. Most patients maintain vision greater than 6/15.

On examination, there may be only a mild sheen or glint in the macular region evident. If a red-free or monochromatic green light is used it is easier to identify the translucent glistening membrane. Thin membranes may be completely translucent, whereas thicker membranes are generally opaque or pigmented and may obscure details of the underlying fundus. The thickened membrane may lead to the appearance of a pseudo-macular hole. As the membrane vessels are seen to be pulled centrally, the macula exhibits striae and heterotopia (displacement). In addition, the superior and inferior arcuate vessels become closer together and straighter than in an uninvolved eye.

Most patients with unocular macular epiretinal membranes maintain a good visual acuity and do not require intervention. It is rare for the membrane to spontaneously detach and so if vision is significantly reduced or patients are very symptomatic with distortion, a pars plana vitrectomy with membrane peel may be indicated.



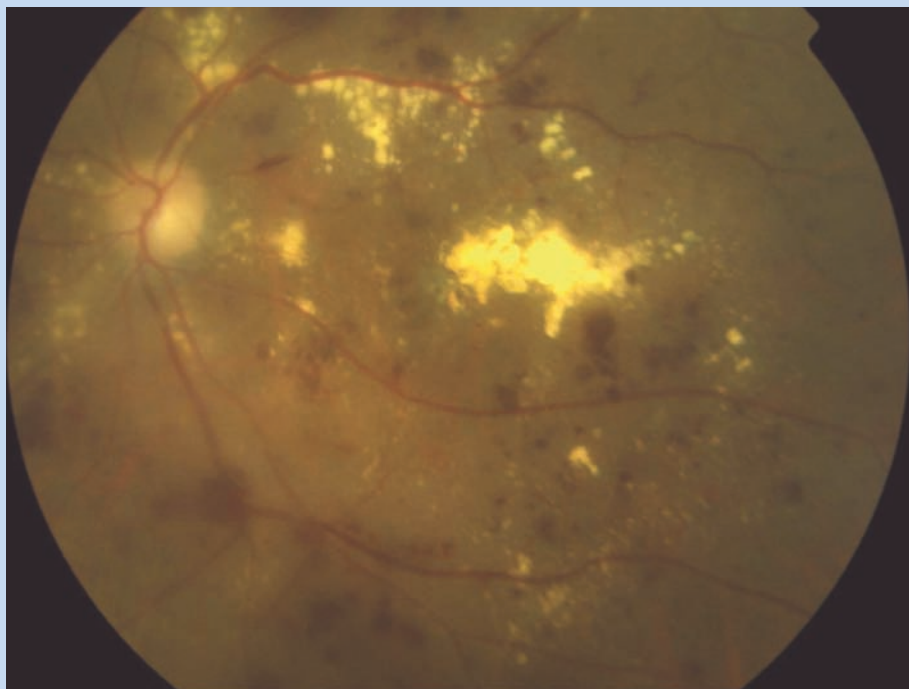
Macular holes

Macular holes are more common in Caucasian women and typically occur from the sixth decade onwards (figure 2). They are generally unilateral but in those affected, there is a 5% incidence of developing a macular hole in the fellow eye.

The patient will report a reduction in their central visual acuity in conjunction with a central scotoma. Amsler grid testing will confirm metamorphopsia. A useful clinical sign is the Watzke-Allen test. If a thin slit beam of light is projected directly onto the fovea, the macular hole will cause a break – a positive result. This is a useful test to help differentiate a pseudo-hole from a true macular hole. OCT is also a very useful non-invasive test to help diagnose macular holes.

A classification for macular holes was first devised by Donald Gass. Stage 1 is classified when the foveal depression is either decreased or absent, and a yellow ring or spot is present. Stage 2 is marked by early, full-thickness hole formation that is less than 400 µm in diameter. Stage 3 is reached when the hole is fully developed, greater than 400 µm in diameter without a Weiss ring. There is often a cuff of subretinal fluid present at this stage. When the vitreous detaches and a Weiss ring is present, the macular hole is classified as stage 4. At this advanced stage, there may be small yellow dots in the centre of the hole at the level of the RPE.

Stage 1 macular holes may be managed conservatively as they frequently spontaneously resolve. If the macular hole advances, then a pars plana vitrectomy is indicated with insertion of gas. Patients need to be counseled preoperatively about the procedure as they must be able to posture for up to two weeks postoperatively in a facedown position. This is an essential procedure in order to allow the gas bubble to tamponade and seal the macular hole. As many of the patients with macular holes are elderly and may have coincident arthritic disease, preoperative counseling is essential. Acute macular holes have better outcomes following surgery compared



➔Figure 3

Severe diabetic maculopathy

to chronic macular holes. Traumatic macular holes can be a complication of blunt trauma to the eye.

Solar maculopathy

Solar maculopathy is part of the differential diagnosis for a macular hole. This injury occurs as a direct result of sungazing. It is acute in onset and its incidence increases around the time of eclipses. Although vision is initially reduced and does not respond to treatment, the long term outcome of these cases is generally good.

Cystoid macular oedema

In cystoid macular oedema (CMO), there is an accumulation of fluid in the outer plexiform and the inner nuclear layers of the retina centered around the foveola. With time, the small fluid filled cysts may join to form larger cystic cavities. CMO has a number of aetiologies – retinal vascular disease such as retinal vein occlusions, diabetic retinopathy and intraocular inflammatory diseases may all cause CMO.

CMO used to be a problem following large incision cataract surgery, however it is now less common with the advances of phacoemulsification. However, it has been reported

following YAG laser capsulotomies and retinal laser photocoagulation and may also be a cause of reduced vision in patients with retinitis pigmentosa. Treatment of CMO is to first treat any underlying exacerbating factors – normalising systemic blood pressure and glycaemic control. Laser photocoagulation may be used to treat CMO associated with retinal vein occlusions providing there is good macular perfusion. Intravitreal injections of steroid or anti-vascular endothelial growth factor (VEGF) agents are also used. Although some treatments result in an anatomical improvement demonstrable on OCT, there is not always a corresponding sustained functional improvement.

Iatrogenic maculopathies

There are many recognised iatrogenic maculopathies. The drug chloroquine used for its anti-malarial and anti-inflammatory properties produces a “bull’s eye” maculopathy. The risk of maculopathy with chloroquine is related to the cumulative dose of the drug ingested and the maculopathy is secondary to sequestration in the melanin of the RPE. Chloroquine maculopathy has several stages – an early sign is the development of a

scotoma to a red target between 4 and 9 degrees from fixation. The patient will also develop mild blue-yellow and protan red-green defects. The most sensitive colour vision tests to detect these changes are the Adam's Desaturation 15 (D-15) test and the American Optical Hardy Rand Ritter test. With time, a bull's eye maculopathy becomes apparent. There is central foveolar pigmentation which is surrounded by a depigmented zone of RPE atrophy which is encircled by a hyperpigmented ring. A safer alternative to chloroquine is hydroxychloroquine.

Two drugs used in the treatment of schizophrenia may also cause macular toxicity – thioridazine and chlorpromazine. When taken in higher than therapeutic doses, both can cause retinal pigmentary disturbance and dysfunction.

Tamoxifen is used as part of the treatment regime for breast cancer and yellow crystalline deposits have been reported in patients on this medication. The macular deposition of yellow crystals is also a feature of canthaxanthin toxicity. This drug is used to enhance the tanning process.

Diabetic retinopathy and maculopathy

When classifying diabetic eye disease,

- Retinal oedema within 500 microns of the centre of the fovea
- Hard exudates within 500 microns of the fovea if these are associated with adjacent retinal thickening
- Retinal oedema one disc area or larger, any portion of which is within one disc diameter of the centre of the fovea.
- Nerve fibre layer infarcts (cotton wool spots)

➔Table 1

Clinically significant macular oedema

it is classified according to both its stage of retinopathy and its stage of maculopathy (figure 3). The term clinically significant macular oedema (CSMO) is used when one of three criteria are met (Table 1) and laser photocoagulation is then indicated. This laser treatment may be either focal or grid depending on the pattern of oedema. Focal laser treatment involves the application of laser burns to the centre of leaking points of circinate rings (figure 4). Grid treatments are used for areas of diffuse retinal thickening. In both types of treatment, the laser burns are light in intensity in comparison to the burns used in panretinal photocoagulation.

It is important to obtain a FFA prior to initiating laser photocoagulative

treatment in order to rule out an ischaemic maculopathy - an ischaemic maculopathy is characterised by an enlarged and an irregular FAZ. Laser photocoagulation is not indicated in cases with macular ischaemia as it doesn't restore perfusion. Patients who have CSMO require prompt referral for laser treatment and medical review - it is important to remember that a patient's maculopathy is a complication of their systemic diabetes and that their blood sugars, cholesterol and blood pressure need to be brought under control.

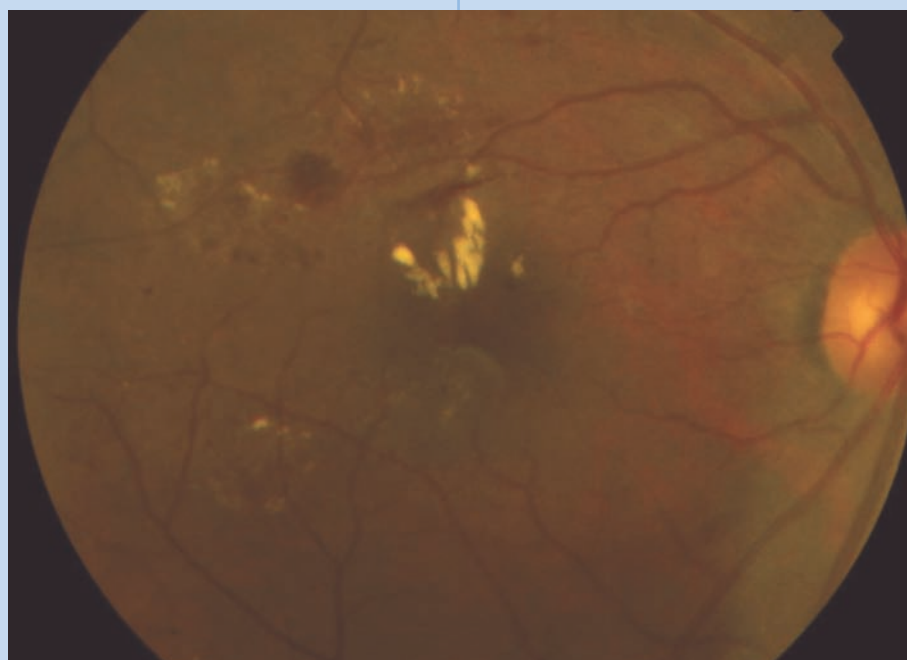
In diabetic patients with a proliferative diabetic retinopathy, the macula may be affected by tractional forces from the fibrosing fronds of neovascularisation. At first, there may just be a wrinkling effect and with time this may proceed to a macular detachment.

Idiopathic juxtafoveolar retinal telangiectasia

Idiopathic juxtafoveolar retinal telangiectasia is an abnormality affecting the blood vessels of the macula. It may be categorised into either unilateral or bilateral groups and may be mistaken for diabetic maculopathy. In the unilateral group of patients, it is primarily men who are affected in the fifth and sixth decades of life. The patients have capillary dilatation and telangiectatic vessels. If there is associated macular ischaemia, the prognosis tends to be worse.

Age related macular degeneration

Age related macular degeneration (AMD) is becoming very prevalent in our ageing population. Risk factors include a positive family history, uncontrolled hypertension and smoking. AMD is divided into two subgroups – the dry and the wet forms. The dry subgroup is the more common, comprising over 85% of cases of AMD. Macular signs in this group include soft drusen, hyperpigmentary changes and geographic atrophy. Patients with this form of AMD have an insidious pattern of visual loss. They will notice central scotomas and have difficulty with fine print and contrast sensitivity. In the



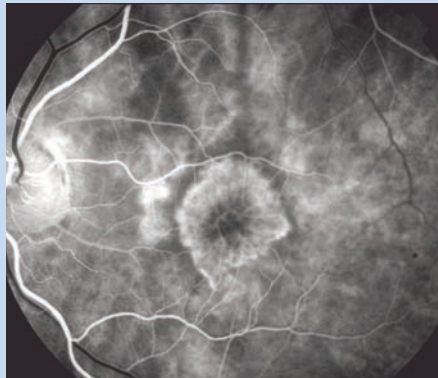
➔ **Figure 4**
Diabetic maculopathy

wet form of macular degeneration, the visual loss is sudden and profound and becomes bilateral in 10% of cases within a year.

The key finding in wet AMD is a CNVM which manifests as a grey-green lesion and is comprised of subretinal blood vessels. There may be associated subretinal fluid and haemorrhages. The CNVMs may be classified according to their location as subfoveal, juxtafoveal or extrafoveal. They may also be classified according to their angiographic appearances as being either classic (new vessels visible on the angiogram) (figure 5) or occult (a blotchy appearance on the angiogram) in nature. Indocyanine green angiography (ICG) is useful in classifying further subtypes of macular degeneration such as idiopathic polypoidal choroidal vasculopathy and retinal angiomatous proliferation. OCT provides useful non-invasive imaging in AMD as it measures retinal thickness and the scanning laser ophthalmoscope (SLO) is a useful adjunct in the management of AMD as it measures levels of lipofuscin. In cases of AMD, fluorescence is increased in sick retinal pigment epithelium and is extinguished when these cells die. An accumulation of lipofuscin accounts for increased signal activity measured with the SLO in AMD.

The treatment of AMD has changed dramatically in recent times. Previously, the standard treatment for wet AMD was to ablate the neovascular membrane with laser photocoagulation. If the CNVM was sub or juxtafoveal, there tended to be collateral damage and macular function would inevitably suffer following the laser treatment. A better outcome was noted in parafoveal CNVMs but patients would notice a paracentral scotoma. However, this treatment was shown to be better than the natural history of wet AMD in the Macular Photocoagulation Study.

Photodynamic therapy (PDT) was developed in order to target only the CNVM and minimise collateral damage. It involves the intravenous injection of a photosensitive dye called Verteporfin which is activated by low energy laser light. The photochemical reaction which ensues activates a thrombotic pathway and closes the CNVM. The



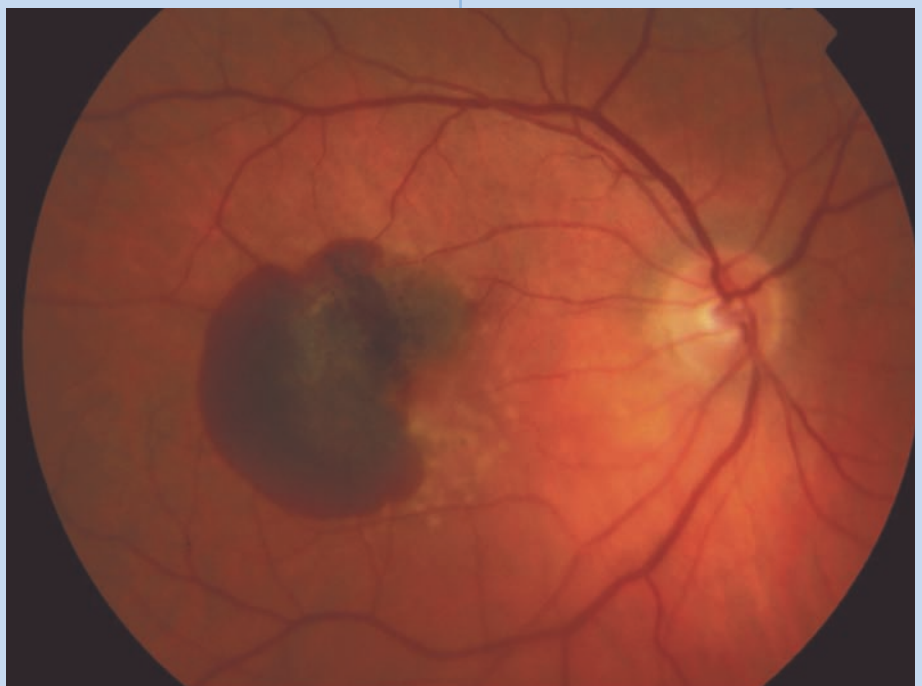
➔Figure 5

Classic choroidal neovascular membrane

'Treatment of AMD with photodynamic therapy' (TAP) study reported the success of PDT in reducing visual loss in cases of subfoveal classic CNVMs. However, it is only with use of anti-VEGF agents that visual recovery has been demonstrated in all types of AMD. VEGF is an important component in angiogenesis and its inhibition reduces the development of CNVMs. The anti-VEGF compounds are injected directly into the vitreous cavity and both the MARINA and ANCHOR studies demonstrated an improved visual outcome in patients treated with these agents. However, there are risks of endophthalmitis, cataract, retinal tears and haemorrhage as it is an invasive

procedure. Commercially available preparations such as Pegaptanib sodium (Macugen) which is isoform 165 specific, and Ranibizumab (Lucentis) which binds all active forms of VEGF A, as well as off-label preparations such as Avastin (Bevacizumab) are in current use. The initial studies with Ranibizumab suggested that monthly intravitreal injections were required and unfortunately, this treatment regimen carries a high cumulative risk. Some centres inject monthly for the first three months and then determine the need for retreatment based on evidence of lesion activity. Combination treatments of anti-VEGF agents either intravitreal or subtenons injections of steroids such as anecortave acetate (RETAANE study) as well as PDT are currently under investigation. If successful, this form of combination treatment will reduce the number of intravitreal injections required.

The advent of OCT has reduced the need for frequent FFAs in monitoring the response of AMD to treatment. Future treatments of wet AMD include an VEGF trap which is smaller and binds to VEGF more avidly than its predecessors. Other therapies in clinical trials directly reduce the amount of VEGF being produced by



➔Figure 6

Large macular haemorrhage

modulating its RNA activity. Surgical translocation of CNVMs is also a recognised treatment for wet AMD.

Prevention is however better than any cure. The age-related eye disease study (AREDS) showed a beneficial effect of anti-oxidant supplementation on retarding the progression to advanced AMD. The AREDS formulation included vitamins C, E, beta-carotene and zinc with copper. The formulation was shown to be statistically significant in reducing the progression to advanced AMD by 25% in patients with bilateral large drusen as well as in patients with advanced AMD already affecting one eye. Oxidative stress is thought to play a significant role in the pathogenesis of AMD. Beta carotene should not be prescribed to smokers as it increased their risk of lung cancer. The antioxidant capabilities of lutein and zeaxanthin may be useful in the prevention of AMD although the US Food and Drug Administration found the evidence insufficient. Some studies have recommended omega-3 fatty acids in the prevention of wet AMD. The AREDS2 study is currently looking to

see whether oral supplementation with lutein and zeaxanthin or omega-3 long-chain polyunsaturated fatty acids will decrease the progression to advanced AMD compared to controls.

The management of macular disorders is in an exciting time of change at present. Newer instruments such as the SLO and OCT allow non-invasive retinal imaging. The array of treatments for AMD has greatly expanded so that visual recovery is now a possibility for this previously blinding disease.

Myopic maculopathy

Choroidal neovascularisation can also be a feature of myopic maculopathy. Myopic maculopathy is generally seen in patients whose refractive error is greater than -6 DS. There is attenuation of the RPE and this may be complicated by the development of lacquer cracks. Macular haemorrhages or "coin lesions" may also cause a drop in central vision (figure 6).

Cerebrovascular accident

The macula although tiny in size has

a large cortical representation in the brain and a stroke involving the occipital lobe may cause isolated macular dysfunction. This may be difficult to detect on standard visual field testing. A central 10-2 visual field or confrontation field testing with a red pin should detect subtle defects.

Conclusion

Disorders of the macula result in poor central visual acuity. However even in patients with profound maculopathy there is preservation of navigational vision. It is vital that this fact is communicated to patients.

About the author

Louise O'Toole is a medical ophthalmologist currently practising in the Beacon Clinic and Medical Optics, Dublin, Ireland. She has been involved in teaching on the Msc in Clinical Optometry at City University, London, particularly in the arena of Ocular Therapeutics and has written several articles in the field for *Optometry Today*.

CET to a Masters - OT and City University join forces to provide CET that suits you

CITY UNIVERSITY and OT have joined forces allowing readers to achieve CET points through to a full Masters in Clinical Optometry. As part of this scheme, OT is running a series of CET articles on topics of direct relevance to optometrists.


This is the third article of the new 2008 series – 'Optometric Management of Posterior Segment Eye Disease'. Successfully complete the MCQs accompanying the current article and receive 2 CET points. Want to know more about the topic? The 'Optometric Management of Posterior Segment Eye Disease' MSc module is running July 13-15 2008. Participants may opt to complete just

the practical sessions or lectures or attend the full three days – the 'Optometric Management of Posterior Segment Eye Disease' CET day is being held on July 13 at City University consisting of cutting edge presentations by leading experts in the field. Extend your participation for a further two days (July 14-15) to obtain in-depth knowledge and hands-on experience. Readers are advised to book early to avoid disappointment – the CET days will be heavily subscribed.

Readers wishing to work towards a postgraduate qualification may obtain 10 postgraduate credits by sitting a three hour examination relating to the OT CET articles. This examination is running on May 28 and is based on all the City CET articles ('Paediatric Optometry' and 'Optometric Management of Anterior Segment Eye Disease') published in 2007. Those attending the three day modules at City may also take an examination to obtain a further 15 postgraduate credits.

Other MSc modules running include: Glaucoma, September 7-9. Alternatively, start your 'Additional Supply/ Supplementary Prescribing' training with the 'Principles of Therapeutics' distance learning module and follow it with the 'Principles of Prescribing' running April 20-22.

For further information see www.city.ac.uk/optometry/msc. Contact Dr Michelle L Hennelly by emailing (m.hennelly@city.ac.uk) or call 020 7040 8352.



Module questions

Course code: c-7981

Please note, there is only one correct answer. Enter online or by form provided

An answer return form is included in this issue. It should be completed and returned to CET initiatives (c-7981) OT, Ten Alps plc, 9 Savoy Street, London WC2E 7HR by April 2 2008.

1 Symptoms of macular disease typically include all of the following except:

- A poor central acuity
- B colour vision difficulties
- C night blindness
- D metamorphopsia

2 Which one of the following is incorrect? Best's disease:

- A is inherited as an autosomally dominant condition
- B is associated with the accumulation of a zeaxanthin-like material
- C is characterised by a pseudohypopyon
- D may be complicated by a choroidal neovascular membrane

3 Which one of the following is incorrect? Stargardt's disease:

- A is inherited as an autosomally recessive condition
- B is associated with a mutation in ABCR
- C has a typical dark choroid seen on fluorescein angiography
- D is characterised by a diminution in lipofuscin-like material in the retinal pigment epithelium

4 Which one of the following is incorrect? In X-linked juvenile retinoschisis:

- A there is a split between the nerve fibre and ganglion cell layers
- B the condition only affects males
- C the pathognomic finding is a radial cystic maculopathy
- D the condition may be associated with diabetes

5 Which one of the following is incorrect? Central serous retinopathy:

- A is associated with the use of corticosteroids
- B is usually a disease of the elderly
- C can have either a 'smokestack' or 'ink blot' appearance on angiography
- D tends to spontaneously resolve

6 Which one of the following is incorrect? Macular epiretinal membranes:

- A may be a complication of uveitis
- B may cause metamorphopsia in advanced cases
- C may be a complication of trauma
- D have a positive Watzke - Allen test

7 Which one of the following is incorrect regarding diabetic retinopathy?

- A it requires a fluorescein angiogram to rule out suspected macular ischaemia prior to laser treatment
- B it may cause a macular detachment
- C it is a complication of systemic diabetes
- D focal laser treatment is used for areas of diffuse retinal thickening

8 All of the following are classified as clinical significant macular oedema except:

- A Retinal oedema within 500 microns of the centre of the fovea
- B Retinal oedema within 500-1000 microns of the centre of the fovea
- C Hard exudates within 500 microns of the fovea if these are associated with adjacent retinal thickening
- D Retinal oedema one disc area or larger, any portion of which is within one disc diameter of the centre of the fovea

9 Which one of the following is incorrect regarding age related macular degeneration (AMD)?

- A the condition may be wet or dry
- B in wet AMD, the condition is always bilateral within one year
- C it is associated with drusen
- D it leads to central visual loss

10 The age-related eye disease study (AREDS) supplements used in age related macular degeneration contain all of the following except

- A Vitamin C
- B Vitamin B
- C Vitamin E
- D Beta carotene

11 Which one of the following is incorrect regarding retinal imaging?

- A ocular coherence tomography is non-invasive
- B the scanning laser ophthalmoscope indirectly measures canthaxanthin
- C ocular coherence tomography can be used to confirm diagnoses
- D ocular coherence tomography can be used to measure retinal thickness

12 Which one of the following is incorrect? AMD may be treated by all of the following except:

- A laser photocoagulation
- B photodynamic therapy
- C surgery
- D gene therapy

Please complete on-line by midnight on April 2 2008 - You will be unable to submit exams after this date - answers to the module will be published in our April 4 issue



Professional Roadshows

Always educating.

Our eyes are always open to professional needs.



Sponsors of accredited distance learning programmes

Johnson & Johnson
Vision Care

THE VISION CARE INSTITUTE
of
Johnson & Johnson Vision Care, Inc.

A DIFFERENT SCHOOL OF THOUGHT™