

## 1 FREE CET POINT

Approved for: Optometrists ✓ Dispensing Opticians ✗

Having trouble signing in to take an exam?  
View CET FAQ Go to [www.optometry.co.uk](http://www.optometry.co.uk)

# Peripheral retinal degenerations

## REFERRAL REFINEMENT PART 10: C-16864 O

**Graham Macalister, PhD, FCOptom, DCLP, Dip Tp (IP)**

**Paul Sullivan, MD, FRCS, FRCOphth**

This article examines retinal degenerations and congenital anomalies which the optometrist may encounter in the periphery of an asymptomatic patient. The key identifying features are described and for each condition, the following questions are asked: Is it a risk factor for retinal detachment (RD)? Is prophylactic treatment required? Does it warrant referral? If so, should it be urgent or routine? If referral is not warranted, is more frequent monitoring by the optometrist required? What advice should be given to the patient?

### Peripheral retinal degenerations and retinal detachment

The increasing adoption of indirect ophthalmoscopy techniques means that optometrists are routinely looking further into the retinal periphery. Imaging instruments, such as the Optomap, have also increased access to this area. Optometrists, therefore, need to be aware of the significance of the conditions that are increasingly likely to be found.

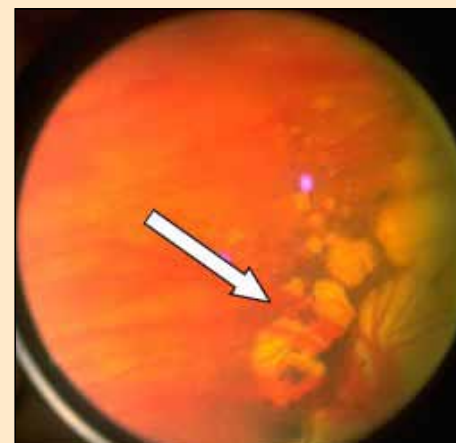In order to decide if a given peripheral retinal degeneration is a risk factor for RD, we must first consider how a detachment arises. Rhegmatogenous retinal detachments (RRD) are the most common and occur when fluid in the vitreous cavity passes through tears or holes in the neurosensory retina and separates it from the underlying retinal pigment epithelium (RPE). Detachment becomes more likely if the break in the neurosensory retina is held open by ongoing vitreoretinal traction, encouraging liquid vitreous that has been mobilised by saccadic eye movements to pass through the open break.<sup>1</sup> Therefore,

if a peripheral retinal degeneration is to be considered a risk factor for RRD then it must predispose the formation of breaks, either through enhanced attachment between the vitreous cortex and the neurosensory retina and/or a weakness of the neurosensory retina itself. Furthermore it is only those conditions that affect the inner retina and its interface with the vitreous, that are likely to be rhegmatogenous. Conditions that affect the outer retina are unlikely to be a risk factor for RD.

### Conditions that affect the outer retina

#### Pavingstone

Also known as cobblestone degeneration, this condition is present in about 25% of the population and appears as well defined yellow white patches between the equator and the ora serrata. It is characterised by the absence of the outer layers of the retina, in particular the choroid, which permits an uninterrupted view of the sclera. Sometimes large blood vessels can also be seen through this window giving the impression of a



**Figure 1**

Pavingstone degeneration (also known as cobblestone) (Image courtesy of Dr HD Riley and the Indiana University School of Optometry, USA)

well-defined red stripe over the white background of the sclera (Figure 1). It is possible that Pavingstone defects are present from birth and should not be considered a degeneration at all. Although these lesions have a striking hole-like appearance, the defect is in the outer retina, leaving the inner layers intact with no predisposition to break formation.

#### CHRPE

Congenital Hypertrophy of the Retinal Pigment Epithelium (CHRPE) is a common benign lesion. It is present at birth and is not a degenerative condition. It is a flat round or oval lesion, which is dark grey or black in colour and up to three disc diameters in size. It is darker and more well-defined than a choroidal naevus because it is more superficial and therefore there is less retinal tissue to dull the appearance and soften the edges. It is an outer retina change and does not affect the vitreo-retinal interface; therefore it does not predispose to retinal detachment. When CHRPE lesions occur in groups, known as bear tracks (Figure 2a), it is worth asking the patient if there is a family history of gastrointestinal problems, in case they are a sign of rare inherited condition of the



bowel known as Familial Adenomatous Polyposis. Individual CHRPE lesions can lose pigment over time, altering the uniform appearance and making recognition more difficult. Some lesions may become almost totally de-pigmented with only a thin rim of residual pigment remaining at the edge, giving the false impression of a hole (Figure 2b).

### Reticular degeneration

Reticular pigmentary degeneration (also known as honeycomb degeneration) is a relatively common finding in the peripheral fundi of older patients. It is characterised by a fine network of pigmentation and has no clinical significance.

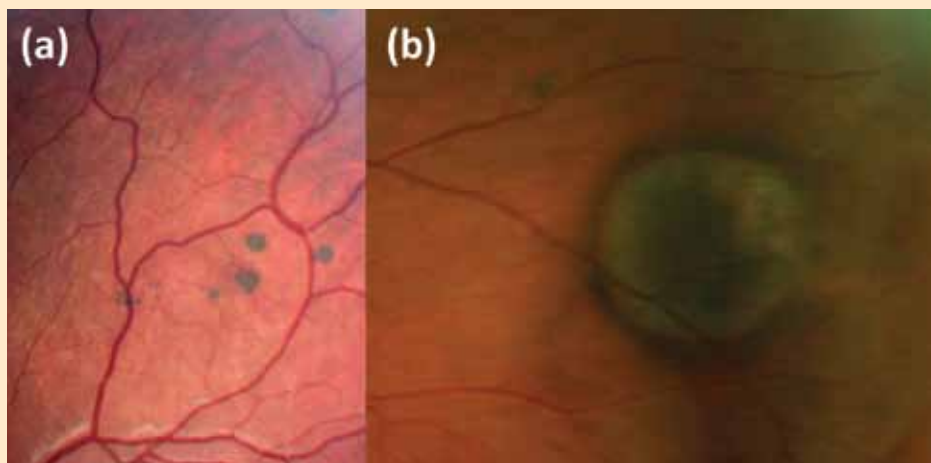
### Peripheral drusen

Optometrists are familiar with drusen that form at the posterior pole in those affected by age-related macular degeneration (AMD). Similar clusters of pale yellow lesions can be found near the equator of the eye in elderly patients (Figure 3). They are not a risk factor for detachment and do not require referral.

## Conditions that affect the inner retina

### White without pressure

White without pressure refers to geographic areas of whiteness in the peripheral retina that are not caused by scleral indentation. It is an optical phenomenon probably related to increased density of collagen fibrils at the interface with the retina. It occurs in 30% of normal eyes and is usually bilateral. There are reports that traction-induced giant retinal tears will follow the posterior border of an area of white without pressure. This does not mean that white without pressure caused the tear, but it may have determined the route that the tear took. It is now believed that white without pressure it is not a risk factor for RRD and there is no need for referral. However,



**Figure 2**

Congenital Hypertrophy of Retinal Pigment Epithelium (CHRPE) (a) a group or "bear track", (b) de-pigmented CHRPE with a thin rim of pigment remaining at the edge

optometrists should be aware that white without pressure can sometimes give the false impression of a retinal break. A true defect in the neurosensory retina will allow the red choroidal reflex to appear brighter in the area of the defect as compared to the adjacent fundus. A similar, but misleading appearance, can occur when an area of seemingly white retina entirely encloses the retina with the normal orange red colouration.

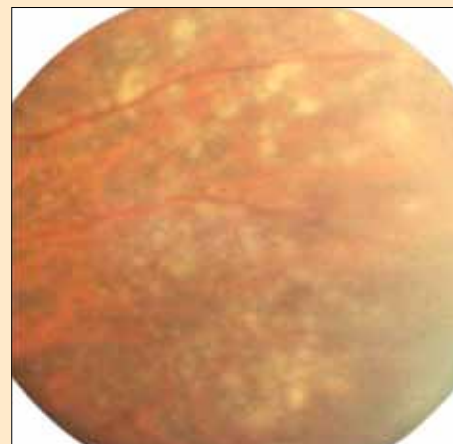
### Microcystoid degeneration

Microcystoid degeneration consists of small vesicles set in an area of greyish white retina near the ora serrata. It is present in all eyes and, although it increases in extent with age, it is not directly responsible for break formation. However, the cysts may give rise to the formation of splits between the layers of the neurosensory retina, producing retinoschisis.

### Retinoschisis

In the age-related form of retinoschisis, cystoid spaces coalesce to form mucopolysaccharide-filled cavities that cause the inner retina to separate from the outer retina (Figure 4). This splitting of the neurosensory retina is present in 7% of the population over 40 years of

age and occurs almost exclusively in hypermetropes, most commonly in the inferior temporal quadrant and often in both eyes. There is total loss of function in the affected area, resulting in an absolute scotoma, but there is no threat to sight because, unlike a retinal detachment, a retinoschisis does not progress from the periphery towards the macula. With retinoschisis, it is rare to see RPE changes, whereas in retinal detachments these changes are relatively common. There is generally no flow of liquid from the vitreous into the schisis cavity, which means that it appears as a smooth bulge that does not change shape or position with eye movements.



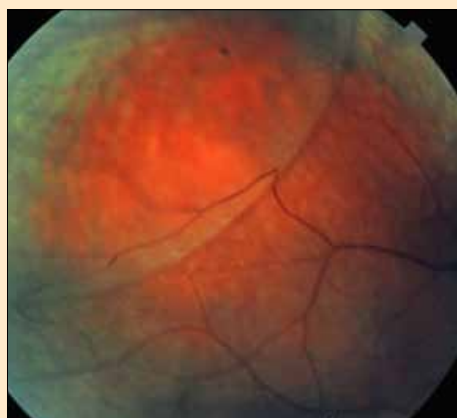**Figure 3**

Peripheral retinal drusen

# 1 FREE CET POINT

Approved for: Optometrists ✓ Dispensing Opticians ✗

Having trouble signing in to take an exam?  
View CET FAQ Go to [www.optometry.co.uk](http://www.optometry.co.uk)



**Figure 4**  
Retinoschisis

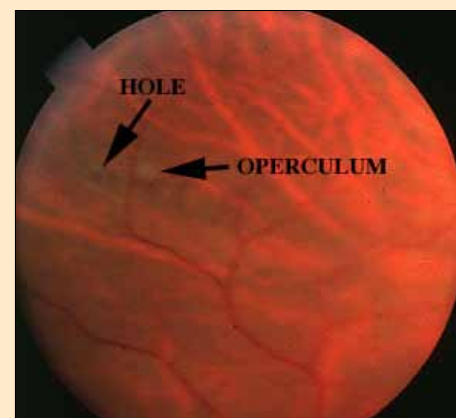
It is possible for breaks to occur, which could then trigger a retinal detachment (detachment of the neurosensory retina from the RPE), but this only happens in 0.05% of cases;<sup>2</sup> there is no need for prophylactic treatment of retinoschisis.

Optometrists who suspect a



**Figure 5**  
Atrophic round hole. Note that the retinal break appears redder than the surrounding retina because of the unobstructed view of the choroid

retinoschisis in an asymptomatic patient should refer on a routine basis and then monitor annually if the



**Figure 6**  
Operculated tear. The operculum remains stuck to the posterior vitreous cortex, which in this case has not detached very far from the retina. Shrinkage means that the operculum appears smaller than the break that it used to occupy (Image courtesy of Dr HD Riley and the Indiana University School of Optometry, USA)

diagnosis is confirmed. The contrasting characteristics of retinoschisis and RRD are shown in Table 1. In particular it is wise to keep to the advice “never diagnose retinoschisis in a myope”.

## Atrophic round holes

Atrophic round holes (Figure 5) are not caused by posterior vitreous detachment (PVD) or by blunt trauma. It is most likely that they are caused by chronic atrophy related to vascular changes. They are generally round or oval in shape and are referred to as atrophic round holes to distinguish them from the U shape tears caused by vitreous traction. Any break in the attached retina appears redder than the surrounding tissue because of the unobstructed view of the choriocapillaris. Note that a peripheral retinal haemorrhage will have irregular margins as it diffuses into the surrounding tissue, whereas a hole has perfectly smooth borders.

The incidence is not related to age and atrophic holes are seen in the young. Many holes are associated with myopia or lattice degeneration (see later). Some

Retinoschisis	Rhegmatogenous Retinal detachment
Split within the neurosensory retina	Neurosensory retina separates from RPE
Smooth, shiny	Rippled, irregular
Stationary on eye movement	Drifts or undulates with eye movements
No flashes or floaters	Flashes, floaters, cobwebs
Bilateral usually	Rarely bilateral simultaneously
7% of population >40 years	0.1% of population
70% hypermetropes	Myopes over-represented
Stable absolute scotoma	Progressive relative scotoma
No breaks	Break present (may be difficult to locate)
No tobacco dust	Tobacco dust
Infero-temporal commonest	Superior-temporal commonest
No pigment disturbance	Pigment disturbance possible if chronic
No spread, innocuous	Sub-retinal fluid spreads, can threaten macula
Routine referral to confirm diagnosis	Urgent referral for treatment

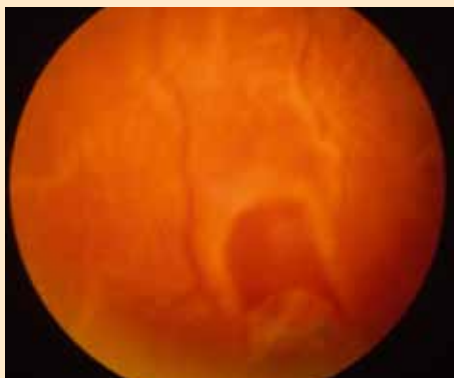**Table 1**

Comparison between the characteristics of retinoschisis and rhegmatogenous retinal detachment





atrophic holes are surrounded by a small area of subretinal fluid (SRF). These have not progressed to a full clinical detachment because there is no vitreous traction to encourage flow through the break. In this situation the RPE is able to pump all the liquefied vitreous into the choroid, with the exception of the immediate zone around the break. A ring of reactive hyperpigmentation at the border of the SRF indicates chronicity and stability. Very rarely an asymptomatic (no flashes or floaters) atrophic hole can slowly progress to a clinical detachment. Where there is a detachment in a young myope with no PVD, the most likely cause is an atrophic hole. Although atrophic round holes can potentially lead to a detachment this is extremely rare<sup>3,4,5</sup> and they do not



**Figure 7**

Flap tear (also known as horseshoe tear or U tear). Note that the apex of the tear always points towards the posterior pole

require treatment and there is no need for referral. It is therefore important to be able to distinguish atrophic round holes from retinal tears, which do require urgent referral (see Table 2). It is useful to refer to a break that results from focal loss

of tissue due to atrophy as a “hole”, while a break induced by vitreous traction is described as a “tear”. Unfortunately this convention is frequently ignored and the two terms are used interchangeably. In an operculated tear (Figure 6), the traction separates a small plug of neurosensory retina from the surrounding retina. This is known as the operculum and it can be seen as a grey disc-shape floater lying over the area of the tear. It remains stuck to the vitreous cortex and moves with it on eye movements. Shrinkage means that it appears slightly smaller than the break that it previously occupied. Operculated tears are also round and the best way of distinguishing them from atrophic round holes is the presence of the disc-shaped floater. Flap tears (Figure 7) produce U or V shape breaks with the apex of the flap pulled into the vitreous cavity but still attached at the anterior border of the tear. Thus the apex of the flap always points towards the posterior pole.

### Lattice degeneration

Lattice retinal degeneration is a common peripheral condition that is present in 8% of eyes, but is more common in myopes. It develops in early adulthood rather than in old age. It has several different ophthalmoscopic presentations, which have previously been described as separate conditions. The classic appearance is a crusty, circumferentially oriented oval patch that appears layered on the surface of the retina. Sometimes there is excess pigment and sometimes fine white lines (sclerosed vessels) criss-cross the patch of degeneration giving rise to the lattice appearance. One variant is characterised by tightly packed “snowflakes” that produce a glistening appearance, which has been described as “snailtrack degeneration”. Histopathology reveals retinal thinning and sometimes small atrophic holes will be evident, which can lead to asymptomatic localised

Feature	Atrophic hole	Operculated tear	Flap tear
Shape	Round or oval	Round with disc shape operculum floating above the break	U shape with central flap
Vitreous traction	None	Traction formed the break but is absent after the operculum has separated	Usually continuous traction
Location	Far periphery	Far to mid periphery	Far to mid periphery
Retinal or vitreous haemorrhages	Never	Rarely	Often
Symptoms (flashes, floaters)	Never (unless clinically significant RD occurs)	Possible in traction phase (or if clinically significant RD occurs)	Frequent in traction phase (or if clinically significant RD occurs)
Incidence of RD	Rare	1/6 <sup>8</sup> (much less if asymptomatic)	1/3 <sup>8</sup>
Prophylactic treatment of break	Never (for exceptions see lattice)	Rarely	Always
Referral	No	Routine (unless significant sub-retinal fluid)	Immediate to A&E

**Table 2**

The features of atrophic round holes are contrasted with those of operculated tears and flap tears

# 1 FREE CET POINT

Approved for: Optometrists  Dispensing Opticians 

Having trouble signing in to take an exam?  
View CET FAQ Go to [www.optometry.co.uk](http://www.optometry.co.uk)

retinal detachment as described above.<sup>6</sup>

The vitreous overlying the area of lattice is liquefied, but there is exaggerated vitreoretinal attachment along its margin. It is this combination (thin retina, strong vitreous attachment and a reservoir of liquefied vitreous) that makes lattice degeneration a risk factor for tractional tears following PVD. However, this does not mean that all areas of lattice should receive prophylactic laser treatment. Although lattice degeneration is a risk factor for RRD, the majority of these patients do not develop a detachment. Only 1% of eyes with lattice changes suffered RRD in a 10-year follow up period<sup>7</sup> and it was concluded that prophylactic treatment should be discontinued. Furthermore, treatment may not always prevent detachment because new breaks can occur in areas not visibly affected by lattice. Referral for lattice, even in the presence of atrophic round holes, is therefore not required.

## Optometric considerations

It may seem to be a contradiction that

lesions such as atrophic round holes and lattice degeneration can be risk factors for RRD, yet they do not warrant referral. Laser retinopexy is routinely applied to retinal tears or detachments and is very effective at preventing visual loss. Why is it not used on those peripheral retinal degenerations that can theoretically lead to a detachment? It is important to understand that it is not always appropriate, or even feasible, to attempt to reduce a disease risk by prophylactic treatment. There are two reasons why this is not done for peripheral degenerations. Firstly, the incidence of RRD secondary to lattice or atrophic holes is extremely low. Secondly, when prophylactic treatment of peripheral degenerations was undertaken in the past, the results did not show overall that it was effective in preventing detachment. This was confirmed by a Cochrane review,<sup>9</sup> which is now widely accepted by ophthalmologists. Laser retinopexy is, therefore, not applied prophylactically to peripheral retinal degenerations. One possible exception is when there is a history of detachment, associated with

lattice degeneration, in the fellow eye.

What should optometrists tell the patient when they identify a risk factor for retinal detachment? They should tell the patient that retinal detachment is a rare condition and that even though features in their eyes have been identified that make this slightly more likely, the risk is still not high. The symptoms of a retinal break or detachment should be described and the patient told to seek advice immediately if they should occur. Emphasise that only sudden changes in floaters are significant. Nervous myopes should be discouraged from trying to constantly monitor their floaters for a small increase in numbers. It is also important to stress that there is no need to modify lifestyle, pastimes or sport. The myth that women can suffer RD as a result of the strains of child birth is totally without foundation.

It can be seen from Table 3 that the only peripheral retinal degeneration that requires referral is retinoschisis. Where there is doubt about the correct differential diagnoses then it is always wise to refer on the basis that it is the most serious condition. Thus, if an area of elevated retina has some features of retinoschisis but some that would suggest detachment then referral would have to be urgent. Treatment is required for retinal tears and detachment and referral refinement for these conditions will be considered in more detail in the next article in this series.

## About the authors

Graham Macalister is a specialist optometrist at Moorfields Eye Hospital. Paul Sullivan is a vitreo retinal consultant at Moorfields Eye Hospital, where he is the director of education.

## References

See <http://www.optometry.co.uk> clinical/index. Click on the article title and then download "references".

Peripheral degeneration	Risk factor for RRD?	Action
Pavingstone	No	None required
CHRPE	No	None required
Reticular	No	None required
Peripheral drusen	No	None required
WWP	No	None required
Microcystoid	No	None required
Retinoschisis	Very rare progression	Refer routinely for confirmation of diagnosis. Then monitor annually
Atrophic round holes	Very rare	Retinal detachment warning. Monitor annually
Lattice	Very rare	Retinal detachment warning. Monitor annually

**Table 3**

Summary of peripheral retinal lesions and actions required



## Module questions

**PLEASE NOTE** There is only one correct answer. All CET is now FREE. Enter online. Please complete online by midnight on October 28, 2011 – You will be unable to submit exams after this date – answers to the module will be published on [www.optometry.co.uk](http://www.optometry.co.uk). CET points for these exams will be uploaded to Vantage on November 7, 2011.

### Course code: C-16864 O

#### 1. Which of the following statements about white without pressure is TRUE?

- a) It represents an area of increased vitreoretinal attachment
- b) It is a risk factor for retinal detachment
- c) It requires "soon referral" to confirm the diagnosis
- d) It requires no action

#### 2. Which of the following statements about retinoschisis is TRUE?

- a) It requires "soon referral" because of the risk of progression to retinal detachment
- b) It is more common in hypermetropes
- c) A relative field defect will be present
- d) Shifting fluid causes its position to change if the patient is examined lying down

#### 3. Which of the following statements about atrophic round holes is TRUE?

- a) They are caused when vitreous traction detaches a circular area of retina
- b) They always require referral because they can progress to a detachment
- c) They appear more red than the surrounding retina
- d) They are more common in hypermetropes

#### 4. Which of the following statements about lattice degeneration is TRUE?

- a) Retinal detachment develops in 8% of patients
- b) It is most common after the age of 60 years
- c) Referral is not required
- d) The white lines visible in lattice represent traction

#### 5. Which of the following statements about CHRPE is FALSE?

- a) It is not a retinal degeneration
- b) Its appearance always remains stable throughout life
- c) It appears to have more well defined borders than a choroidal naevus
- d) Multiple CHRPE can be associated with an inherited bowel condition

#### 6. Which of the following statements about retinal degenerations is TRUE?

- a) Patients with lattice degeneration should be advised to give up body contact sports
- b) Women should be counselled about the risk of retinal detachment during childbirth
- c) Pavingstone degeneration is characterised by defects in the outer retina making it a risk factor for retinal detachment
- d) The only peripheral retinal degeneration that may require referral is retinoschisis

### Course code: C-16942 O/D/CL

#### 1. According to market research, what is the current average age that females begin using cosmetics?

- a. 10.9 years
- b. 13.7 years
- c. 15.2 years
- d. 17.0 years

#### 2. The silicone hydrogel contact lens material Lotrafilcon B demonstrates resistance to deposits owing to which of the following features?

- a. Plasma surface treatment
- b. Embedded wetting agents
- c. High water content
- d. Packaging saline additive

#### 3. Investigators from the University of Alabama discovered microbial contamination in what percentage of mascara tubes?

- a. 25%
- b. 32%
- c. 37%
- d. 45%

#### 4. An association between dryness symptoms and make-up use was found in what proportion of non-contact lens wearing patients?

- a. 19%
- b. 26%
- c. 53%
- d. 64%

#### 5. Contact lens contamination by make-up and/or make-up remover can cause which of the following?

- a. Compromise to the performance of the lens
- b. Changes to the physical structure of a lens
- c. Changes to the physical properties of the lens
- d. All of the above

#### 6. Which of the following is the LEAST appropriate option to select for a contact lens wearer experiencing an undesirable effect from ocular cosmetics?

- a. Fitting a daily disposable contact lens
- b. Fitting a lens with a surface treatment that resists spoilage
- c. Use of a hydrogen peroxide cleaning regimen
- d. Fitting a RGP contact lens



I wish my practice could have:

- ✓ interactive, hands-on training
- ✓ professional advice
- ✓ tailored to our needs
- ✓ at my convenience
- ✓ in my practice

You can.

Speak to your CIBA VISION®  
Business Development Manager.

CIBA VISION

Practice  
ACADEMY

BRINGING THE ACADEMY  
FOR EYECARE EXCELLENCE™  
TO YOUR PRACTICE.