

COURSE CODE: C-8299

1 CET POINT

ENTER ONLINE AT WWW.OTCET.CO.UK



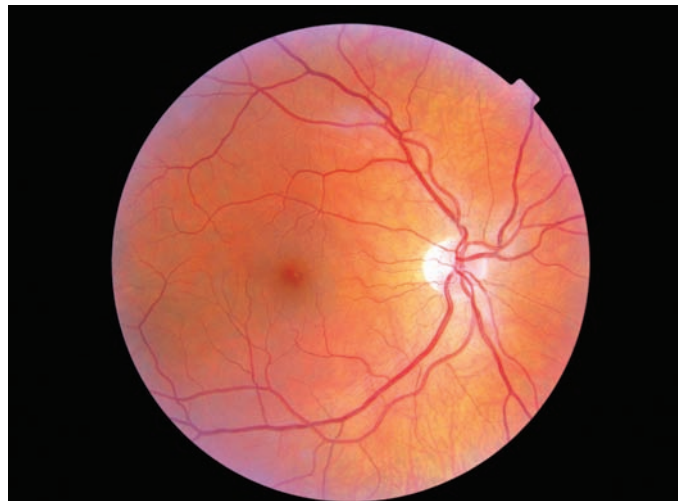Variations in appearance of the normal optic nerve head

Professors David B Elliott and John G Flanagan
from the Universities of Bradford and Waterloo

The vast majority of patients examined in primary eye care have normal, healthy eyes. To discriminate between ocular disease and the normal eye, it is essential to know the many presentations that a normal eye can make and a collection of photographs of these normal variations at the optic nerve head is presented to supplement the information provided in atlases of ocular disease. The following is adapted from *Clinical Procedures in Primary Eye Care* (2007, 3rd edition) and its associated website (<http://evolve.elsevier.com/Elliott/eyecare/>).

Size and shape

The optic nerve head or disc comes in a variety of shapes and sizes. The mean average Caucasian optic disc area, excluding high myopes, is between 2.1mm² and 2.8mm² with a range



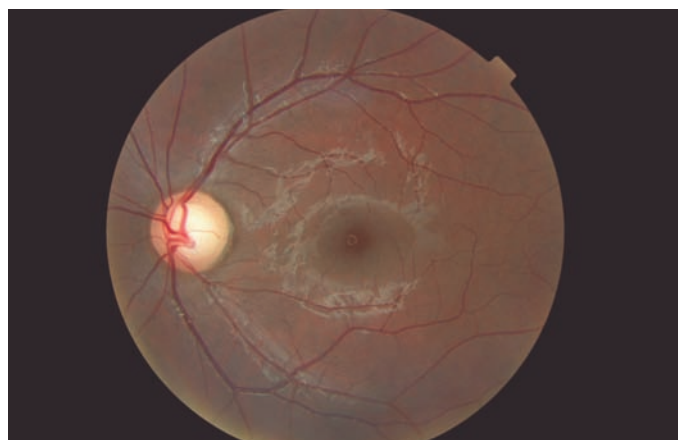⇒ Figure 1

A small, flat optic nerve head of a young Caucasian patient

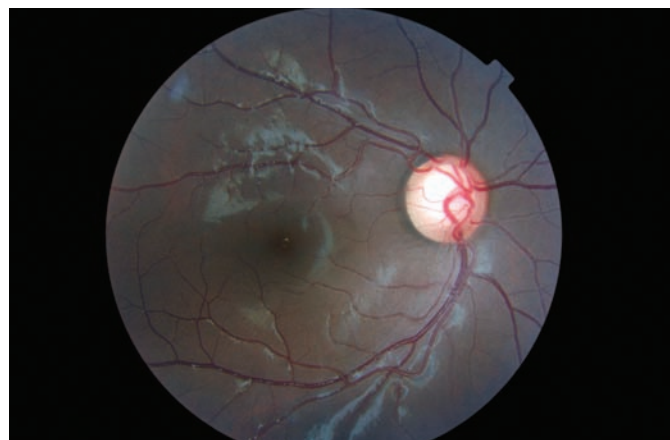between 0.80mm² to 6.00mm².¹ The average vertical disc diameter is 1.8mm with a horizontal disc diameter of 1.7mm. Discs have been shown to be smaller on average in Caucasians (Figure 1), and progressively larger in Mexicans, Asians and African North Americans (Figures 2 & 3).² Disc size is also larger in myopes beyond -8 D and smaller in hyperopes greater than +4 D.¹ Oval discs (Figure 4) are often found with corneal astigmatism and the direction of the longest optic disc diameter can indicate the axis of astigmatism.³

Optic cupping

The central proportion of the nerve head usually contains a depression called the 'cup'. This is often associated with an area of pallor due to the lamina cribrosa reflecting through in the absence of axons and their associated capillaries. However, in some cases the cup can extend beyond the area of pallor, so that this should not be used as an indicator of cup size during 2-D evaluations such as provided by direct ophthalmoscopy. Rather the kinking of blood vessels as they pass over the edge of the cup should be used as an estimate of the cup position. As discussed above, discs can vary considerably in size, yet approximately the same number of axons (about 1 million) leave the eye via the optic nerve head. Therefore large optic discs typically have larger cupping because of the absence of axons in the middle of the disc as the neurons leave the retina in the larger rim tissue of larger discs. The physiological cup-to-disc ratio (CDR) is normally less than 0.60, but is relative to the size of the disc so that smaller cupping should be seen in a small-sized disc and larger cupping is expected in large discs (Figs. 2 and 3). For this reason, a 0.30 CDR in a small disc may be more indicative of glaucoma than a 0.70 CDR if it is in a large-sized disc (e.g., Garway-Heath et al.⁴), highlighting the importance of assessing disc size. The CDR is typically measured in the vertical meridian as the cup tends to enlarge in the vertical meridian in glaucoma. A large physiological cup



⇒ **Figure 2**
A large optic nerve head with a large cup (CDR ~ 0.65) of a 20-year old Asian patient. Many reflections are present around the blood vessels and in a ring shape around the macula.



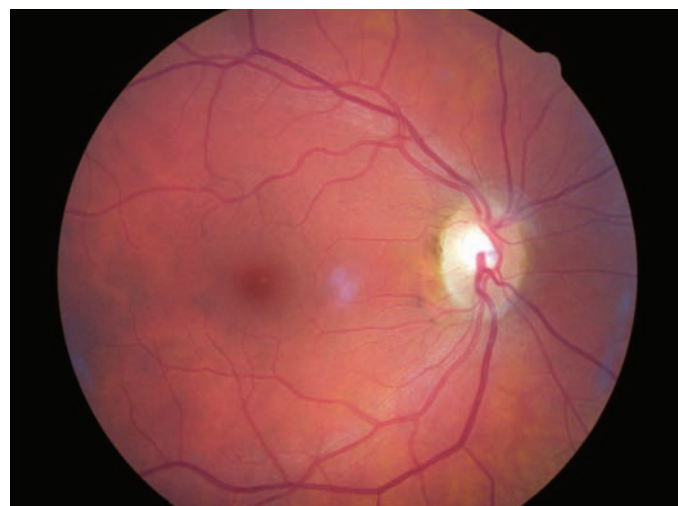
⇒ **Figure 3**
A large optic nerve head with a large cup (CDR ~ 0.70) of a 45-year old British African-Caribbean patient. The patient had normal discs and retinal nerve fibre layer according to ocular coherence tomography and GDx assessments and Humphrey central visual fields were normal. Once again, there are many reflections around the retinal blood vessels.

(>0.60 vertical CDR) can also be seen in highly myopic patients. An attempt should be made in any primary care eye exam to categorise the optic disc size as small (vertical diameter <1.5mm), average or large (vertical diameter >2.2mm). Disc diameter can be estimated using a Volk type lens and the measuring graticule found on most slit-lamps. For vertical diameter measurement, adjust the slit beam height to match the disc then note the graticule reading. Note that the measured optic disc size will differ depending on the condensing lens and slit lamp used.⁵ For example, when using a Haag Streit slit lamp and Volk lenses, the approximate correction factor will be 1.0x for a 60 D lens, 1.1x for a 78 D and 1.3x for a 90 D lens. It should also be noted that the CDR is generally determined to be larger when the optic disc is examined stereoscopically with indirect ophthalmoscopy than when examined monocularly with direct ophthalmoscopy,⁶ which illustrates the limitation of a 2-D approach. The vertical CDRs indicated for the photographs

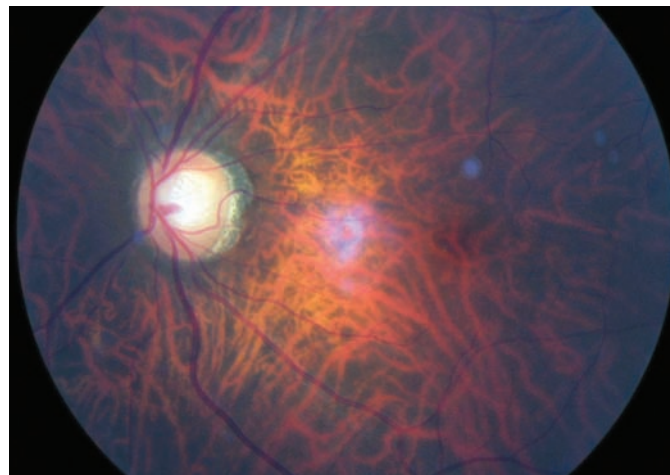
presented here are based on the 2-D diagrams. The optic nerve heads and cups of the two eyes are typically mirror images of each other and differential diagnosis of many optic nerve head anomalies is provided by an inter-eye comparison. The neural rim tissue should be thickest in the Inferior region of the disc, then the Superior and Nasal, being thinnest in the Temporal region, so that normal neural rim tissue follows the ISN'T rule.

Lamina cribrosa

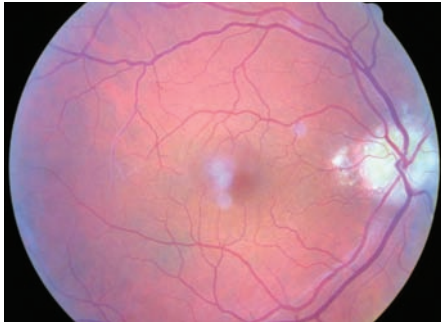
Seen in about 30% of eyes⁷ as grey dots at the bottom of the optic cup (Figure 5). It is a sieve-like structure of largely connective and glial tissue that is continuous, although embryologically distinct, with the scleral coat. Perhaps not surprisingly, it is more visible in larger discs and larger cups and this appears to be the only reason that visible lamina cribrosa has a higher prevalence in patients with open-angle glaucoma.⁷



⇒ **Figure 4**
An oval optic nerve head.

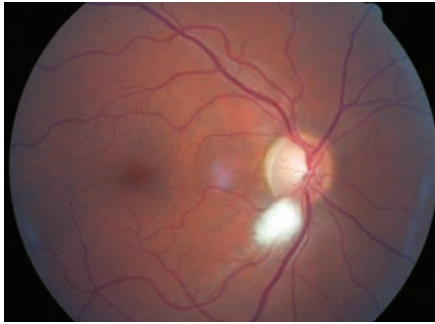


⇒ **Figure 5**
Clearly visible lamina cribrosa in a large cup with a myopic crescent in a striking tessellated (tigroid) fundus.



➔ **Figure 6**

Drusen in the optic nerve head. The blurred purplish spots are artefacts, likely from dust in the camera system. There is also some scattered light from the edge of the pupil around the periphery of the image.



➔ **Figure 7**

Myelinated nerve fibres at the inferior pole of the optic nerve head. There is a purple spot artefact between the optic nerve head and macula, likely due to dust in the camera system.

Drusen of the disc

A familial, typically bilateral condition, found in about 0.3% of patients, which becomes more obvious with age.⁸ In children, they may be buried in the nerve head and not seen and the disc appears swollen, so that the condition is sometimes called pseudopapilloedema. They are golden, autofluorescent, glowing, calcific globular deposits that sit in front of the lamina cribrosa (Figure 6). They are typically found in small discs with little or no cupping and this appearance can mask signs of early glaucoma. Although typically benign they can shear blood vessels and/or nerve fibres, leading to haemorrhages (2-10%) and visual field loss (~75%), some of which can be progressive.⁸ Visual field monitoring is essential.⁹ Areas of peripapillary pigment atrophy can be seen after resolution of any haemorrhages.⁸

Myelinated nerve fibres

Found in about 1% of patients and represents myelin sheathing of the optic nerve fibres that extends beyond the lamina cribrosa and presents a superficial, white, feathery opacification which hides any underlying retinal blood vessels. They are usually continuous with the optic nerve head (Figures 7 & 8), although small discrete patches of myelinated nerve fibres can appear and may mimic a cotton wool patch. They are typically benign, although may cause visual field loss at threshold. A small number are characterized by ipsilateral extensive myelinated nerve fibres, anisometropic myopia, amblyopia, and strabismus.¹⁰ In most cases, myelinated nerve fibres remain unchanged over time. However, loss of myelinated nerve fibres may occur due to a central demyelinating process or the result of direct axonal destruction or nerve fibre layer ischaemia¹¹ and has been reported in central retinal artery occlusion, uncontrolled glaucoma, anterior ischemic optic neuropathy, optic neuritis and Behçet disease and after plaque radiotherapy for choroidal melanoma and pars plana vitrectomy.

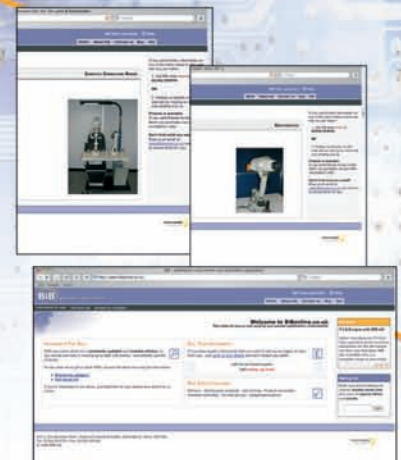Nerve fibre layer striations

These are brightest at the superior and inferior poles, where the nerve fibre layer is thickest and are best seen in young patients, particularly those with heavily pigmented fundi (Figure 9). The striations are caused by the tubes of astrocytes that surround the retinal ganglion cell axon. Fundus photography, particularly digital, may provide a better assessment of the nerve fibre layer than fundus biomicroscopy.¹² Nerve fibre layer striations are best seen with the green (red-free) filter as the lower wavelengths do not penetrate the nerve fibre layer and are more readily reflected back. Focal wedge-shaped defects in the nerve fibre layer striations can occasionally be detected in patients with glaucoma and although diffuse nerve fibre layer is more common in glaucoma, it is more difficult to detect.

Buying or selling quality ophthalmic instruments?...

Get an instant quote online at www.bibonline.co.uk

For the first time in the UK, you can view images of the actual instruments on our stock list.



Detailed accurate and up-to-date stock list:

it's live, and constantly updated so for an opportunity to get a really great deal.

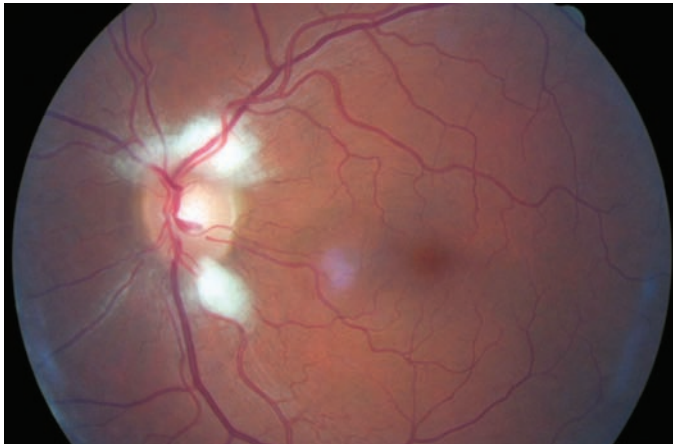
www.bibonline.co.uk

E: sales@bibonline.co.uk

T: 01763 274774

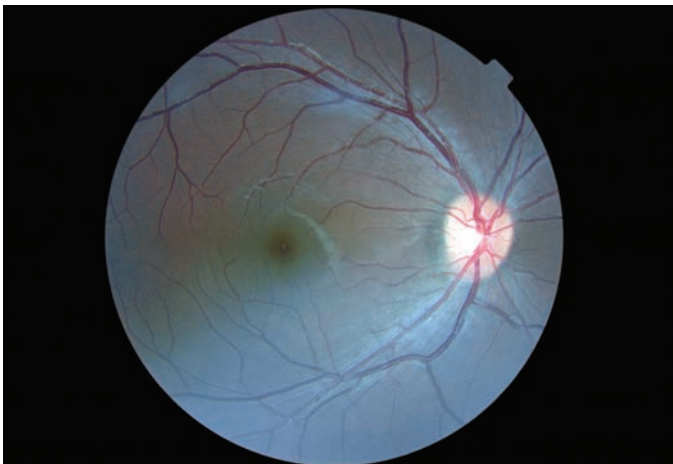F: 01763 274754





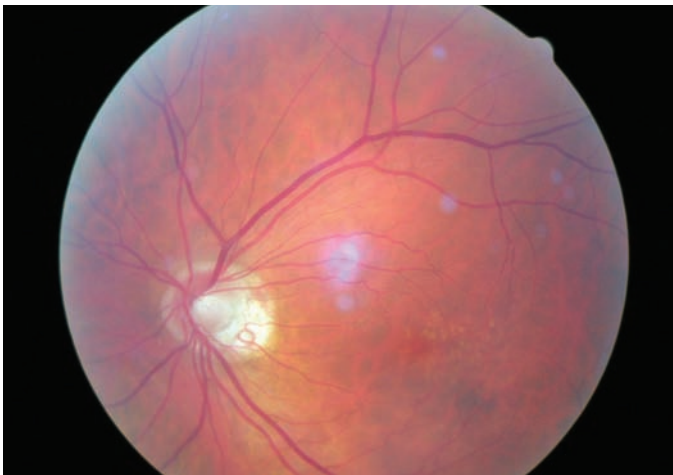
⇒ Figure 8

Myelinated nerve fibres at the superior and inferior poles of the optic nerve head. There is some light scatter from the edge of the pupil inferiorly.



⇒ Figure 9

Highly visible nerve fibre striations in an Asian fundus. The image also shows an oval nerve head and obvious macular pigment.



⇒ Figure 10

Peripapillary atrophy (PPA). There appears to be a ring of beta zone, with temporal alpha zone. The image is slightly more washed out compared to those from younger patients (e.g. figs 1-3) due to light scatter from early cataract. Drusen are visible in the macular region.

Peripapillary atrophy (PPA)

PPA can be categorised into zone alpha and beta.¹³ Zone beta PPA is found adjacent (bordering) to the disc and is present in about 15% of normal eyes (Figure 10). It is more common in glaucoma, but more importantly it can be a sign of progressive disease if it gets larger. The RPE and choriocapillaris are lost and all that is visible are the large choroidal vessels and sclera. Zone alpha is present in nearly all normal eyes and is characterised by irregular hyper and hypopigmented areas in the RPE, either on their own or surrounding zone beta PPA. PPA is most commonly found at the temporal edge of the disc. It should be differentially diagnosed from high myopic atrophy and malinserted optic discs.

Tilted discs & optic disc malinsertion

The tilt can be seen with the 3-D view of fundus biomicroscopy. With direct ophthalmoscopy it is seen as an oval disc whose edges may not be exactly focussed simultaneously. In the tilted disc syndrome, the disc or discs are commonly tilted inferior nasally with a nasal staphyloma (bulging of the sclera) and situs inversus, where the temporal blood vessels first course towards the nasal retina before sharply changing course (tilted disc in Figure 11 and a normal disc in the fellow highly myopic eye in Figure 12). Tilted discs are thought to be caused by an incomplete closure of the embryonic foetal fissure, similar to the aetiology of a coloboma.¹⁴ The condition is benign, although the area of nasal staphyloma can produce a temporal visual field defect. Tilted disc syndrome can be in one or both eyes and the binocular condition can produce bi-temporal field defects. These can usually be differentiated from chiasmal lesions as the bi-temporal field defects cross the vertical midline and the field defect can be improved if retested with a higher myopic correction. Tilted discs are associated with corneal astigmatism and myopia and the direction of the longest optic disc diameter can indicate the axis of corneal astigmatism.³

Much more common is optic disc malinsertion, which is a simple insertion of the optic nerve at an acute angle and without the appearance of rotation of the optic nerve, nasal staphyloma or situs inversus. The malinsertion is almost always bilateral and the malinserted discs are mirror images of each other, typically elevated nasally, tilting downwards temporally and with a temporal scleral and/or choroidal crescent. Photographs from the right and left eyes of a patient with malinserted discs are shown in Figures 13 and 14.

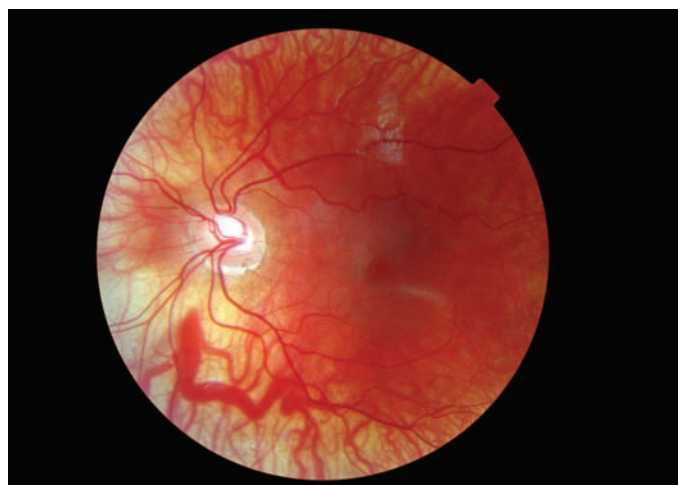
Acknowledgement

We thank the students of the University of Bradford for sitting as subjects for many of the photographs and Dr Lisa Prokopich and the University of Waterloo eye clinic for provision of some of the other photographs.

About the authors

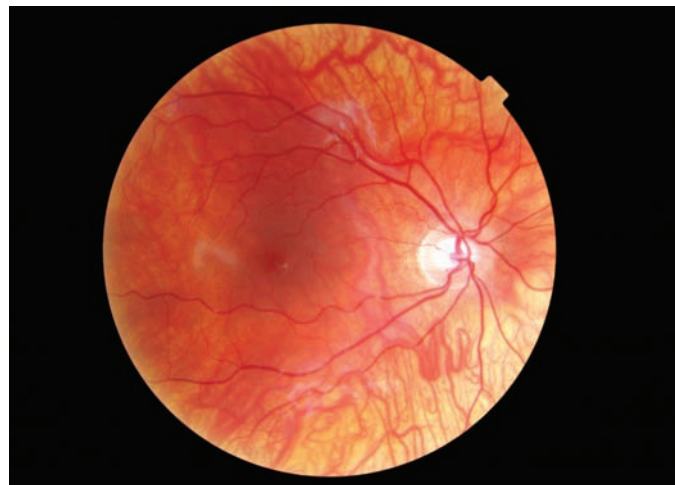David B Elliott is Professor of Clinical Vision Science, Department of Optometry, University of Bradford, UK.

John G Flanagan is Professor at the School of Optometry, University of Waterloo and Professor, Department of Ophthalmology and Vision Sciences, University of Toronto, Canada.



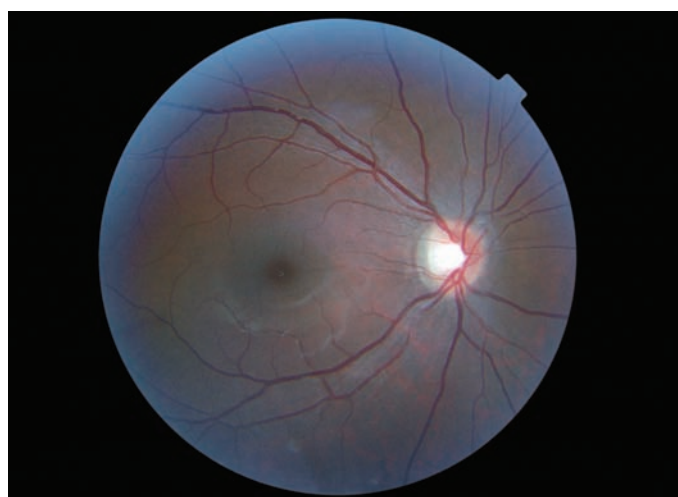⇒ Figure 11

Tilted disc syndrome with situs inversus. This Caucasian eye is also highly myopic and astigmatic, with a thin retina and visible underlying choroid.



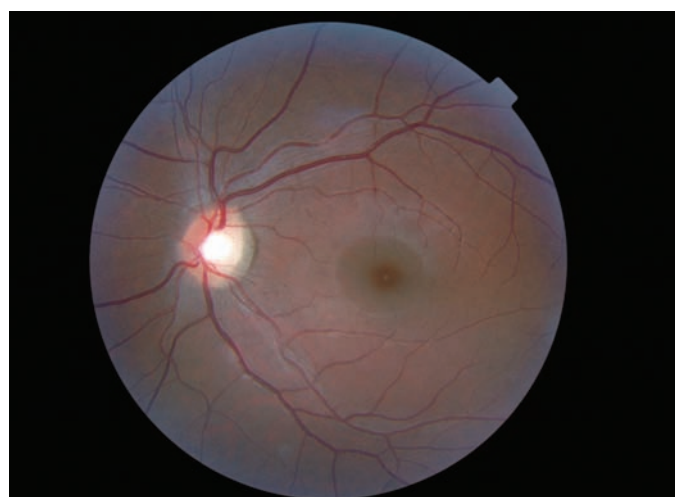⇒ Figure 12

The image from the right eye of the same patient shown in fig. 11. This eye is also highly myopic and has a thin retina and visible underlying choroid.



⇒ Figure 13

The image from the right eye of an Asian patient with optic nerve malinsertion. There is some light scatter from the edge of the pupil.



⇒ Figure 14

The image from the left eye of the same patient shown in fig. 13. Nerve fibre striations and macula pigment are also clearly visible.

References

- Jonas JB (2005). Optic disk size correlated with refractive error. *Am J Ophthalmol* **139**: 346-348.
- Jonas JB, Budde WM, Panda-Jonas S (1999). Ophthalmoscopic evaluation of the optic nerve head. *Surv Ophthalmol* **43**: 293-320.
- Jonas JB, Kling F, Grundler AE (1997). Optic disc shape, corneal astigmatism, and amblyopia. *Ophthalmology* **104**: 1934-1937.
- Garway-Heath DF, Ruben ST, Viswanathan A, Hitchings RA (1998). Vertical cup/disc ratio in relation to opti disc size: its value in the assessment of the glaucoma suspect. *Br J Ophthalmol* **82**: 1118-1124.
- Ansari-Shahrezaei S, Maar N, Biowski R, Stur M (2001). Biomicroscopic measurement of the optic disc with a high-power positive lens. *Invest Ophthalmol Vis Sci* **42**: 153-157.
- Varma R, Steinmann WC, Scott IU (1992). Expert agreement in evaluating the optic disc for glaucoma. *Ophthalmology* **99**: 215-221.
- Healey PR, Mitchell P (2004). Visibility of lamina cribrosa pores and open-angle glaucoma. *Am J Ophthalmol* **138**: 871-872.
- Aumiller MS (2007). Optic disc drusen: complications and management. *Optometry* **78**: 10-16.
- Lee AG, Zimmerman MB (2005). The rate of visual field loss in optic nerve head drusen. *Am J Ophthalmol* **139**: 1062-1066.
- Straatsma BR, Foos RY, Heckenlively JR, Taylor GN (1981). Myelinated retinal nerve fibers. *Am J Ophthalmol* **91**: 25-38.
- Williams AJ, Fekrat S (2006). Disappearance of myelinated retinal nerve fibers after pars plana vitrectomy. *Am J Ophthalmol* **142**: 521-523.
- Blumenthal EZ, Weinreb RN (2001). Assessment of the retinal nerve fiber layer in clinical trials of glaucoma neuroprotection. *Surv Ophthalmol* **45**: S305-312
- Jonas JB, Budde WM (2000) Diagnosis and Pathogenesis of Glaucomatous Optic Neuropathy: Morphological Aspects. *Prog Ret Eye Res* **19**: 1-40.
- Sowka J, Aoun P (1999). Tilted disc syndrome. *Optom Vis Sci* **76**: 618-623.

Module questions

Course code: C-8299

Please note, there is only one correct answer. Enter online by March 5 2008.

It should be completed online at www.otcet.co.uk by March 5 2008.

1. The average cup-to-disc ratio viewed by direct ophthalmoscopy is:

- A The same size compared to when viewed by indirect ophthalmoscopy.
- B Larger compared to when viewed by indirect ophthalmoscopy.
- C 0.30 when using either direct or indirect ophthalmoscopy.
- D Smaller compared to when viewed by indirect ophthalmoscopy.

2. Drusen of the disc can cause:

- A Papilloedema.
- B Relatively little as it is essentially a benign condition.
- C Secondary glaucoma.
- D Haemorrhage and progressive visual field loss.

3. Of the following, which is the most significant risk factor for primary open-angle glaucoma?

- A 0.60 cup-to-disc ratio.
- B Tilted disc.
- C 0.50 cup-to-disc ratio in a small disc.
- D Oval cup-to-disc ratio.

4. Of the following, which is the most significant risk factor for primary open-angle glaucoma?

- A Visible large pores of the lamina cribrosa.
- B Zone alpha peripapillary atrophy.
- C Visible nerve fibre striations.
- D Zone beta peripapillary atrophy.

5. Myelinated nerve fibres:

- A Are benign and cause no visual loss.
- B Can cause visual field loss, regress with certain conditions and should be monitored.
- C Can cause visual field loss and should be given a non-urgent referral on first diagnosis.
- D Can progress and regress with certain ocular conditions and should always be given a non-urgent referral on first diagnosis.

6. Nerve fibre layer striations are best seen:

- A In undiagnosed glaucoma at the inferior and superior poles.
- B In the peri-macular bundle.
- C At the superior and inferior poles.
- D In treated glaucoma at the inferior and superior poles.

Please complete on-line by midnight on March 5 2008 - You will be unable to submit exams after this date - answers to the module will be published in our March 7 issue



the nation's local
home optician

An ever increasing number of practices are relying on The Outside Clinic to solve their patient requests for domiciliary eye tests.

Under the Code of Ethics and Guidelines for Professional Conduct - Aug 06, it states: "If an Optometrist does not offer a domiciliary service, information should be available in practice as to how a patient, carer, General Medical Practitioner (GMP) or others may access such services provided by other optometrists."

If you're having difficulties with your home visits, call us today

0800 85 44 77
www.outsideclinic.com

theoutsideclinic
community opticians

Working in association with **Lloydspharmacy** 
Your local health authority